

# A Case Series of Papillary Thyroid Carcinoma in Patients with Acromegaly

Zineb Ait Si Ali<sup>1</sup>, Oussama Jaddi<sup>1</sup>, Sana Rafi<sup>1</sup>, Ghizlane El Mghari<sup>1</sup>,  
Nawal EL Ansari<sup>1</sup>

<sup>1</sup>Department of Endocrinology, Diabetology, Metabolic Diseases and Nutrition Cadi Ayyad University,  
Mohammed VI University Hospital, Marrakech, Morocco

Corresponding Author: Zineb Ait Si Ali

DOI: <https://doi.org/10.52403/ijshr.20240136>

## ABSTRACT

**Introduction:** Acromegaly is a rare disorder with an approximate incidence of 3-11 new cases per million of population per year. It's associated to an increased risk of benign and malignant neoplasms, especially thyroid, colorectal and breast cancer.

**Case Series:** We report 2 cases of two patients followed in our department for acromegaly who were diagnosed also with papillary thyroid carcinoma.

**Discussion and Conclusion:** IGF1 inhibit cell apoptosis and promote cell proliferation in multiple tissues. An association between IGF1 levels and cancer risk such as thyroid cancer was detected. Careful screening for thyroid cancer, with periodic thyroid examination, should be an important part of the management of acromegalic patients.

**Key words:** Acromegaly - malignancy - papillary thyroid carcinoma

## INTRODUCTION

Acromegaly is a rare disorder with an approximate incidence of 3-11 new cases per million of population per year and a prevalence of approximately 60 per million [1]. It's usually caused by excessive growth hormone production from pituitary adenoma, resulting in excessive growth of body tissues and other metabolic

dysfunctions. [2,3]. In adult, acromegaly is characterised by facial features; large lower jaw, prominent forehead, and large hands and feet; this symptom occurs after the growth plates are fused, distinguishing acromegaly from gigantism, which occurs before the fusion of growth plates [2,4].

The issue of increased risk of benign and malignant neoplasms in patients with acromegaly remains the topic of debate from many years [5]. Several studies have documented a high frequency of thyroid cancer mostly papillary thyroid cancer in patients with acromegaly. The reported prevalence is 4.7–11%, which is much higher than that in the general population [6].

The most commonly discussed mechanism of this entity is increased level of growth hormone, leading subsequently to increased level of insulin-like growth factor 1. The positive correlation between the level of circulating IGF-1 and the risk of colorectal, breast or thyroid cancer had been demonstrated [5].

The aim of our study, is to highlight the association of papillary thyroid carcinoma and acromegaly through the description of our reported cases, and to discuss the latest features regarding this association in the light of literature reviews.

## CASE SERIES

### Case 1

A 55-year-old male was referred to our endocrinology department, for suspicion of acromegaly by his gastrologist, who was following him for internal hemorrhoids. Medical history of the patient included; hypertension diagnosed 3 years before treated with bi-therapy. Total thyroidectomy for multinodular goiter with lymph node dissection at the age of 48, anatomopathological analysis concluded to papillary thyroid carcinoma with lymph node metastases [T3N+(6/12)M0], then the patient received two radioiodine therapy cures of 100mci, Whole body scan after, showed no sign of residual localization, thyroglobulin levels on L-thyroxine remained under 0.1ng/ml with negative thyroglobulin antibodies levels. Clinical examination noted prominent chin, protruding brow bones, thick lips, enlarged nose, macroglossia, tooth spacing, deep voice, enlarged hands and feet, rough skin and excessive sweating. After comparing to old pictures, we realized that the signs had been installed at least 20 years before diagnosis. The patient had also an overweight BMI : 29,03kg/m<sup>2</sup>.

On paraclinical findings; IGF 1 was elevated to 671.9 ng/ml, pre-diabetes with hemoglobin A1c: 5.9% and fasting blood sugar: 1.07g/l, thyroid stimulating hormone (TSH): 0.5 mIU/ml, free T4: 19 pmol/l, follicle stimulating hormone (FSH); 8.25 mIU/ml, luteinizing hormone (LH): 4.6 IU/L, testosterone: 2.55 ng/ml, cortisol: 9.35 µg/dL at 8 am, and prolactin: 36.4 ng/ml.

Hypothalamo-pituitary magnetic resonance imaging (MRI) was performed and showed a macroadenoma in the pituitary gland of 12\*12\*11mm (figure 1)

Two months later, the patient underwent transsphenoidal surgery, anatomopathological analysis confirmed the diagnosis of pituitary adenoma, Immunohistochemistry staining showed positivity for GH, FSH, LH and prolactin.

Six months after, MRI noted post-surgical remodeling of the sellar region with no detectable signs of progression, IGF-1 and GH under OGTT were elevated. Treatment with Lanreotide LP was started (120mg per 28 days).

the patient's overall clinical condition was improved, and Control assessment is currently in progress.

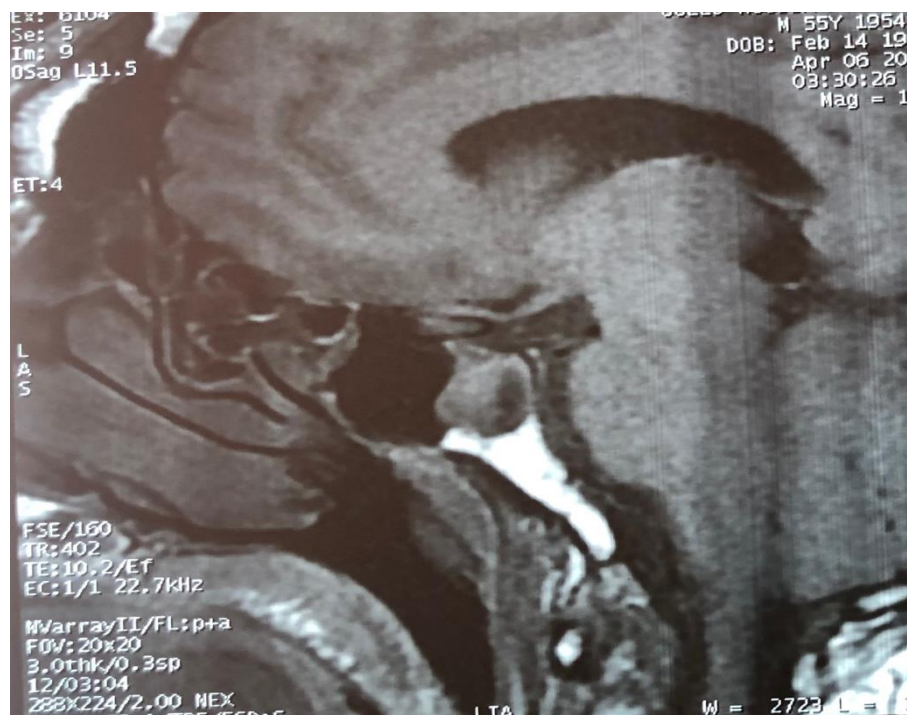


Figure 1: Hypothalamo-pituitary magnetic resonance imaging of our patient (case 1) showing pituitary macroadenoma.

## Case 2

A 42-year-old male was referred to our endocrinology department, for papillary thyroid carcinoma follow up.

Medical history of this patient included diabetes diagnosed three years before treated with Metformin. The patient underwent total thyroidectomy for multinodular goiter, anatomopathological analysis revealed a papillary thyroid microcarcinoma, no adjuvant treatment was indicated, control assessment showed no signs of recurrence; normal whole-body scan, neck ultrasound was normal and Thyroglobulin at 0.1ng/ml with negative thyroglobulin antibodies.

During the first medical consultation, we noted an acromegalic signs with prominent chin, protruding brow bones, thick lips,

enlarged nose, macroglossia, tooth spacing, deep voice, enlarged hands and feet, rough skin. The patient reported that this signs have been gradually appearing since the last six years. He also mentioned Nocturnal snoring and profuse sweating.

Paraclinical examination showed an elevated IGF-1 level to 1071 ng/ml (Normal for the age 83-237), thyroid-stimulating hormone (TSH): 1.15 mIU/ml, free T4: 17.2 pmol/l, follicle-stimulating hormone (FSH); 3.3 mIU/ml, luteinizing hormone (LH): 3.2 IU/L, testosterone: 2.34 ng/ml, cortisol: 15.9 µg/dL at 8 am, and prolactin: 9.01 ng/ml.

Hypothalamo-pituitary magnetic resonance imaging (MRI) was performed and showed a macroadenoma in the pituitary gland of 16\*15\*13mm (**figure 3**). Transsphenoidal surgery is scheduled

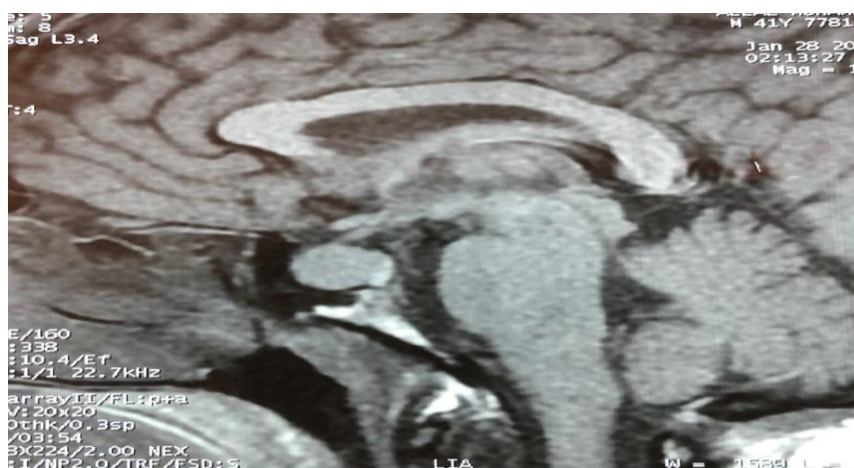

Figure 2: Hypothalamo-pituitary magnetic resonance imaging of our patient (case 2) showing pituitary macroadenoma.

## DISCUSSION

Acromegaly is a chronic disease resulting from excessive secretion of growth hormone (GH), which stimulates the production of insulin-like growth factor-1 (IGF1). Since high levels of IGF1 inhibit cell apoptosis and promote cell proliferation in multiple tissues, it is biologically plausible to consider acromegalic patients at increased risk of cancer [6,7,8].

Although cancer is not a significant cause of mortality in acromegalic patients, it has been reported that the risk of developing benign and malignant tumors in acromegaly is greater than in the general population [9]. An association between IGF1 levels and

cancer risk such as colorectal, thyroid, breast, and prostate cancer was detected [3,7]. Wolinski et al [10], reported in their study that the risk of developing any type of malignant tumour was more than three times that of the control group. Among malignant tumors, the risk of thyroid cancer was significantly elevated over fivefold.

In addition, the frequency of goiter in acromegaly is high and constitutes a risk factor for thyroid cancer [9]. Kim et al [6], found thyroid nodules and thyroid cancer in 75.0% (45/60) and 25.0% (15/60) of acromegaly patients, respectively. This prevalence of thyroid cancer is higher than in the general population of Korea (2.5%).

The presence of IGF1 receptors in human thyroid cells was first demonstrated in 1989 by Yashiro et al [11], who also found that IGF1 binding in neoplastic tissue was considerably higher than in surrounding normal tissue. IGF-1 promotes thyrocyte proliferation and transformation and suppresses cell apoptosis by binding to the IGF-1 b receptor [6,12]. This hypothesis has been confirmed by several immunohistochemical studies [7]. Keskin et al [12], reported that expression of IGF1 in the tumoral tissue of patients with acromegaly related papillary thyroid carcinoma is more common, the overexpression of IGF-IR in thyroid cancer samples was found using immunohistochemistry and in situ hybridization, and IGF-I was found to be produced either paracrine or autocrine. They also identified strong expression of IGF-1 in papillary thyroid carcinoma of acromegalic patients.

Some studies, also proved the correlation between IGF1 and IGF1 receptor expression and the aggressiveness of thyroid cancer [7]. BRAF is an important oncogene that is frequently mutated in papillary thyroid carcinoma, and mutation occurs in 45 - 62.5 % of cases [6, 13]. A study by Aydin et al [14], compared acromegalic and non-acromegalic patients with differentiated thyroid cancer and found that acromegalic patients presented a remarkably low prevalence of the BRAF V600E mutation. Also Kim et al [6]. reported a similar result, detecting the BRAF mutation in the PTC sample of only 1 in 11 patients (9.1%).

Keskin et al [7,12], compared protein expression by immunohistochemical staining in the papillary thyroid carcinoma of 13 acromegalic patients and 20 patients without acromegaly, reporting similar BRAF expression in both groups, while IGF1 and Galectin 3 expression were significantly higher in the acromegalic group. In addition, the 13 acromegalic patients with papillary thyroid carcinoma had higher levels of GH and IGF1 than the 300 acromegalic patients without

acromegaly. Thus, BRAFV600E mutation may not be the primary mechanism of PTC carcinogenesis in acromegalic patients [6].

Thyroid nodules can change dynamically with acromegaly activity [15]. Most patients with acromegaly are regularly followed by an endocrinologist, and thyroid malignancies are not known to be more aggressive in acromegalic patients, but periodic thyroid examination is useful for identifying complications at earlier stages [8,16].

The increased thyroid cancer incidence with no change in mortality may be partly due to active surveillance of acromegalic patients [3].

In the literature, the evolution of thyroid carcinoma in acromegalic patients has not been fully described. Danilowicz et al [17] did not identify any risk factors responsible for worse evolution, and they reported that thyroid carcinoma in acromegalic patients did not have a more aggressive evolution compared to non-acromegalic patients with thyroid carcinoma. Nevertheless, the significance of these results is limited by the small number of included patients with acromegaly and patients with high-risk differentiated thyroid carcinoma. Extending the follow-up period and including more patients with high-risk thyroid carcinoma could provide evidence of the validity of these findings [17].

## CONCLUSION

In conclusion, multiple studies have shown an increased prevalence of malignancies in patients with acromegaly, especially an elevated risk of thyroid cancer. Careful screening for thyroid cancer, with periodic thyroid examination, should be an important part of the management of acromegalic patients.

### *Declaration by Authors*

**Acknowledgement:** None

**Source of Funding:** None

**Conflict of Interest:** The authors declare no conflict of interest.

## REFERENCES

1. Carroll PV, Joshi MN. Acromegaly. [Updated 2022 Sep 7]. Endotext [Internet]. South Dartmouth (MA): MDText.com, Inc.; 2000-. Available from: <https://www.ncbi.nlm.nih.gov/books/NBK279097/>
2. Adigun OO, Nguyen M, Fox TJ, et al. Acromegaly. [Updated 2023 Feb 2]. In: StatPearls [Internet]. Treasure Island (FL): StatPearls Publishing; 2023 Jan-. Available from: <https://www.ncbi.nlm.nih.gov/books/NBK431086/>
3. Xiao T, Jiao R, Yang S, et al. Incidence and risk factors of cancers in acromegaly: a Chinese single-center retrospective study. *Endocrine* 82, 368–378 (2023). <https://doi.org/10.1007/s12020-023-03447-y>
4. Zhao Y, Wang Y, Zhang X, et al. Papillary Thyroid Carcinoma in Patients with Acromegaly from a Single Center in China. *World Neurosurg.* 2021;149:e22-e28. doi:10.1016/j.wneu.2021.02.101
5. Ruchala M, Wolinski K. Health-Related Complications of Acromegaly-Risk of Malignant Neoplasms. *Front Endocrinol (Lausanne)*. 2019;10:268. Published 2019 Apr 30. doi:10.3389/fendo.2019.00268
6. Kim HK, Lee JS, Park MH, et al. (2014) Tumorigenesis of Papillary Thyroid Cancer Is Not BRAF-Dependent in Patients with Acromegaly. *PLoS ONE* 9(10): e110241. doi:10.1371/journal.pone.0110241
7. Terzolo M, Puglisi S, Reimondo G, et al. Thyroid and colorectal cancer screening in acromegaly patients: should it be different from that in the general population?. *Eur J Endocrinol.* 2020;183(4):D1-D13. doi:10.1530/EJE-19-1009
8. Stefan A, Loana D, Florentina B, et al Association between acromegaly and papillary thyroid cancer: A case series *Endocrine Abstracts* (2022) 81 EP675 | DOI: 10.1530/endoabs.81.EP675
9. Bałdys-Waligórska A, Gołkowski F, Krzentowska A, et al. A case of acromegaly and disseminated follicular thyroid carcinoma. *Endokrynol Pol.* 2010;61(5):497-501.
10. Wolinski K, Stangierski A, Dyrda K. et al. Risk of malignant neoplasms in acromegaly: a case-control study. *J Endocrinol Invest* 40, 319–322 (2017). <https://doi.org/10.1007/s40618-016-0565-y>
11. Yashiro T, Ohba Y, Murakami H, et al. Expression of insulin-like growth factor receptors in primary human thyroid neoplasms. *Acta Endocrinologica* 1989 121 112–120. (<https://doi.org/10.1530/acta.0.1210112>)
12. Keskin F, Ozkaya H, Ferahman S, et al (2018). The Role of Different Molecular Markers in Papillary Thyroid Cancer Patients with Acromegaly. *Experimental and Clinical Endocrinology & Diabetes*, (), a-0629-9223-. doi:10.1055/a-0629-9223
13. Wu Xia, Gao Lu, Guo Xiaopeng, et al, (2018). GH, IGF-1, and Age Are Important Contributors to Thyroid Abnormalities in Patients with Acromegaly. *International Journal of Endocrinology*, 2018, 1–8. doi:10.1155/2018/6546832
14. Aydin K, Aydin C, Dagdelen S, et al, “Genetic alterations in differentiated thyroid cancer patients with acromegaly,” *Experimental and Clinical Endocrinology & Diabetes*, vol. 124, no. 03, pp. 198–202, 2016.
15. Dogansen SC, Salmaslioglu A, Yalin GY, et al. Evaluation of the natural course of thyroid nodules in patients with acromegaly. *Pituitary* 22, 29–36 (2019). <https://doi.org/10.1007/s11102-018-0923-1>
16. Heidarpour M, Rezvanian H, Kachuei A. Acromegaly and papillary thyroid carcinoma: A case series. *J Res Med Sci.* 2019;24:81. Published 2019 Sep 30. doi:10.4103/jrms.JRMS\_969\_18
17. Danilowicz K, Sosa S, Gonzalez Pernas MS, et al. Acromegaly and thyroid cancer: analysis of evolution in a series of patients. *Clin Diabetes Endocrinol* 6, 24 (2020). <https://doi.org/10.1186/s40842-020-00113-4>

How to cite this article: Zineb Ait Si Ali, Oussama Jaddi, Sana Rafi, Ghizlane El Mghari, Nawal EL Ansari. A case series of papillary thyroid carcinoma in patients with acromegaly. *International Journal of Science & Healthcare Research.* 2024; 9(1): 271-275. DOI: <https://doi.org/10.52403/ijshr.20240136>

\*\*\*\*\*