

Treatment of Open Femur Fracture of the Gunshot Injuries by Interlocking Nail in Aden, Yemen

Omar Abdulsalam Abdullah Hadi Mohsen

Orthopedic Resident, Algamhoria Teaching Hospital and Alsalam Hospital, Aden, Yemen

DOI: <https://doi.org/10.52403/ijshr.20230250>

ABSTRACT

Background: Gunshot wounds remain a major clinical problem with bone injuries.

Objective: To evaluate the treatment procedures of open fractures due to gunshot and the outcome

Patients and methods: This was a prospective study conducted during January 2019 to December 2020.

The enrolled patients were males having open fracture of femur due to gunshot or explosive shrapnel injuries and the data collected directly from patients by interview. The fractures were classified according to Gustilo classification.

All patients underwent with stainless steel intramedullary nail with proximal and distal screws.

Follow up of patients was for six months. Data were processed using the SPSS, version 22. Fisher test was used and p-value < 0.05 was considered as statistically significant.

Results: The study cases were 62 male patients. Age ranged between 17 to 50 years and the mean age was 25.7 ± 7.2 years. Gustilo open fracture type 3A seen in (98.4%) patients. Most of the site of femur fracture was at mid shaft (67.8%).

Half of patients (53.3%) had time interval of first debridement within 7 – 12 hours,

Predominantly debridement was performed once in (82.4%) patients.

Mostly, delayed primary closure was carried out within 3 – 7 days in (71%) patients. IM nail was carried out mostly (56.6%) of cases within 7-14 days.

We found superficial infection and acute osteomyelitis each one in (6.5%) patients.

Pulmonary embolism found in (3.2%) patients. Deep wound infection, chronic osteomyelitis, deep vein thrombosis, each one was in (1.6%) patient.

We found shortening in (1.6%) patient, mal-union in (1.6%) patient, non-union in (3.2%) patients and stiffness found in (3.2%) patients.

Conclusion: Intramedullary nailing provide an effective device in patients with gunshot fractures of femur and it is safe and provides strong fixation, rotational stability and earliest return to functional status.

Key words: Open femur fracture, gunshot injuries, interlocking nail

INTRODUCTION

Gunshot injuries are escalating social and medical dilemma in many Western and some developing countries and incidence of gunshot injury is increasing worldwide due to the fact that there is increasing violence in the society [1,2].

Low velocity wounds are more common in civilian practice and are usually less severe, whereas high velocity wounds are more severe in nature, causing widespread tissue damage, and are more commonly seen in the military setting [3].

The injuries at the extremities might involve complex soft tissues, bone, musculotendinous, vascular and nerve

injuries. The management of these injuries could be challenging and have become a continuous burden on community and hospital resources around the world [4].

Fractures caused by gunshots are becoming increasingly common in urban hospitals and trauma centers [5]. When the long bones are involved, the injury results in comminuted open fractures, which pose a challenging problem to orthopedic surgeons [6].

Gunshot wounds remain a major clinical problem with bone or joint injuries comprising a major portion of gunshot wound injuries and it is paramount for orthopedic surgeons to be thorough in the treatment of patients with these injuries [7]. Comminuted fractures due to gunshot injuries are a challenging problem for orthopedic surgeons [4].

Management of patients with an intramedullary nail (IM) inserted into the femur is the standard of care for surgical fixation for most femoral shaft fractures [8]. Intramedullary locking nail have proved to be of considerable advantage when treating complex, comminuted or segmental femoral shaft fractures. Intramedullary nailing has many theoretical and practical advantages over other forms of external and internal fixation in terms of stable and reliable fixation with early weight bearing [9]. The straight tubular anatomy of femoral shaft is ideally suited to intramedullary nailing. Nails are inserted with relative ease without the extensile exposure. Various designs of interlocking nailing systems allowing closed nailing techniques have been used in the treatment of femoral shaft fractures since the first "de tensor" nail was described by Kuntscher in 1968 [10].

The aim of the study was to evaluate the treatment procedures of open fractures due to gun shot and the outcome of this open

fracture of femur treated by interlocking nails.

Patients and methods:

Study design: This study is a prospective descriptive study.

Setting: The study conducted in Algamhoria Teaching Hospital and Alsalam Hospital in Aden, Yemen. The management of such patients in this hospital relies on orthopedic surgeons who have wide experiences in dealing with such condition.

Study population: the enrolled patients in this study were males having open fracture of femur due to gun shot or explosive shrapnel injuries and were admitted during the period January 2019 to December 2020.

Inclusion criteria:

All patients who had open fracture of femur shaft due to firearm injuries during the mentioned period.

Data collection:

The data collected by the author directly from patients and /or relatives by interview, physical examination, laboratory, and radiological studies. All data were recorded into special records

Firstly, patients were resuscitated in emergency room and prophylactic broad-spectrum antibiotics cefuroxime, gentamycin and metronidazole were given intravenously. X-ray with antero-posterior and lateral views were done. The fractures were classified according to Gustilo open fracture classification. All the patients underwent debridement one time or more according to wound situation and back slap or skeletal traction were done for patients with open fracture Gustilo type IIIa and temporary external fixation was done for patients with Gustilo type IIIb then delayed primary closure was done then one week or more later after wounds healed. Open reduction internal

fixation by intramedullary nail with interlocking proximal and distal screws.

All cases underwent with stainless steel intramedullary nail with proximal and distal screws. Physiotherapy started second day after internal fixation and partial weight bearing help with two axillary crutches. Follow up of patients was for six months.

Statistical analyses: Data were processed using the statistical program SPSS, version 22. We expressed distribution of variables using means and standard deviation (SD). Fisher test was used and p-value < 0.05 was considered as statistically significant.

RESULTS

The total number of the patients was 62 with femur open fractures. All the study patients were males. Their age ranged between 17 to 50 years and the mean age being 25.7 ± 7.2 years.

The variables of patients and the age groups illustrated in Table 1 and Figure 1.

Thirty eight (61.2%) patients were in age group 21-35 years old followed by the age group ≤ 20 years old 17 (27.5%) .

The least number of patients was among the age group > 35 years old - 7 (11.3%).

Table 1 and Figure 1 showed that injuries were in the left side 42 (67.8%) then the right side 20 (32.2%). In addition, Table 1 and Figure 1 showed that Gustilo open fracture type 3A was seen in 98.4% patients. Regarding the site of femur fracture 67.8% of patients at mid shaft, while those with fracture at proximal and distal shaft consisted 14.5% and 17.7% respectively.

Table 1: Distribution of various variables of the study patients (n = 62)

Variable	Range	Mean	No	%
Sex:				
Males			62	100
Females			0	0.0
Age range (years):	17 – 50			
Mean age \pm SD* (years):		25.7 \pm 7.2		
Age groups (years):				
≤ 20			17	27.5
21-35			38	61.2
> 35			7	11.3
Side of injury:				
Left			42	67.8
Right			20	32.2
Gustilo open fracture type:				
3A			61	98.4
3B			1	1.6
Site of femur fracture:				
Proximal shaft			9	14.5
Mid shaft			42	67.8
Distal shaft			11	17.7

SD*: Standard deviation

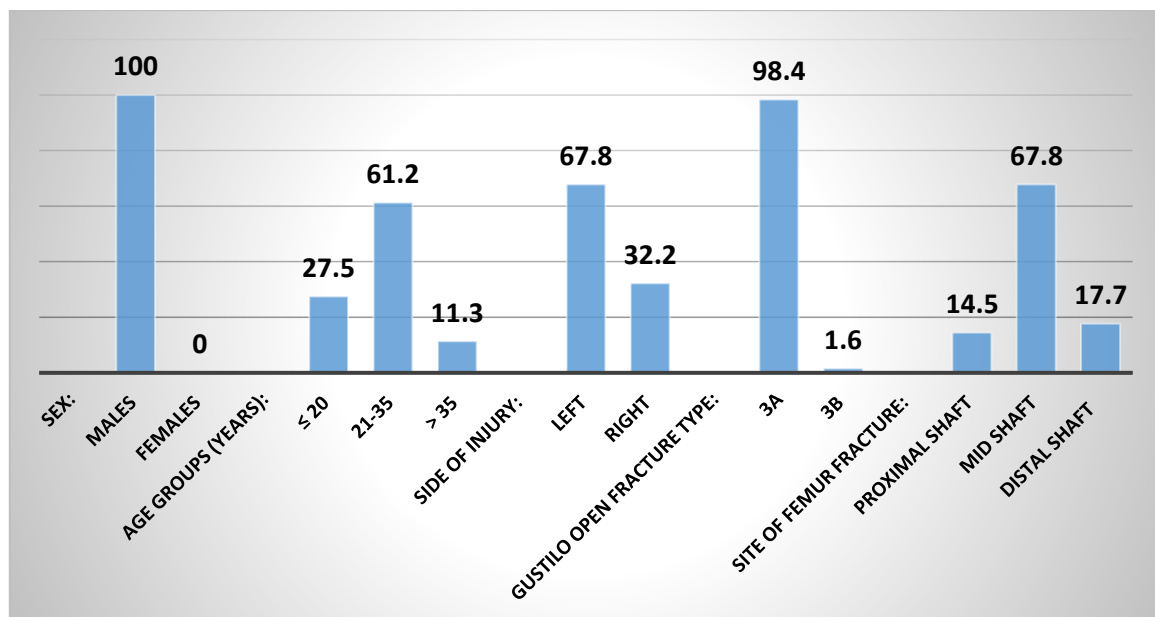


Figure 1: Proportions of various variables of the study patients (n = 62)

Table 2 illustrates the management's variables for treatment of femur fracture. Nearly more than half of patients (53.3%) had time interval of first debridement within 7 – 12 hours, followed by those with interval ≤ 6 hours 24 (38.7%). Predominantly debridement was performed once among 51 (82.4%) of patients. Mostly, delayed primary closure was carried out within 3 – 7 days among 44 (71%) of patients, followed by 8-14 days in 15 (24.2%) cases. IM nail was carried out mostly 35 (56.6%) of cases within 7-14 days.

Additionally, Table 2 and Figure 2 revealed the complications of infections. There was superficial infection in 4 (6.5%) patients, deep wound infection in 1 (1.6%) patient, acute osteomyelitis in 4 (6.5%) patients, chronic osteomyelitis in 1 (1.6%) patient. Deep Vein Thrombosis was found in 1

(1.6%) patient and pulmonary embolism found in 2 (3.2%) patients.

Table 2: Management variables of treatment and complications

Variables	No	%
Time interval first Debridement (hours):		
≤ 6	24	38.7
7 – 12	33	53.3
> 12	5	8.0
Debridement numbers:		
One time	51	82.4
Two times	10	16.0
Four times	1	1.6
Delayed Primary Closure DPC (days):		
3 – 7	44	71.0
8 – 14	15	24.2
≥ 15	3	4.8
Time of intervention IM nail (days):		
7 – 14	35	56.6
15 – 21	17	27.4
≥ 22	10	16.0
Subtotal	62	100
Superficial infection	4	6.5
Deep wound infection	1	1.6
Acute osteomyelitis	4	6.5
Chronic osteomyelitis	1	1.6
Deep Vein Thrombosis	1	1.6
Pulmonary embolism	2	3.2
Subtotal		
Postoperative complications	13	21.0
None complications	49	79.0
Total	62	100

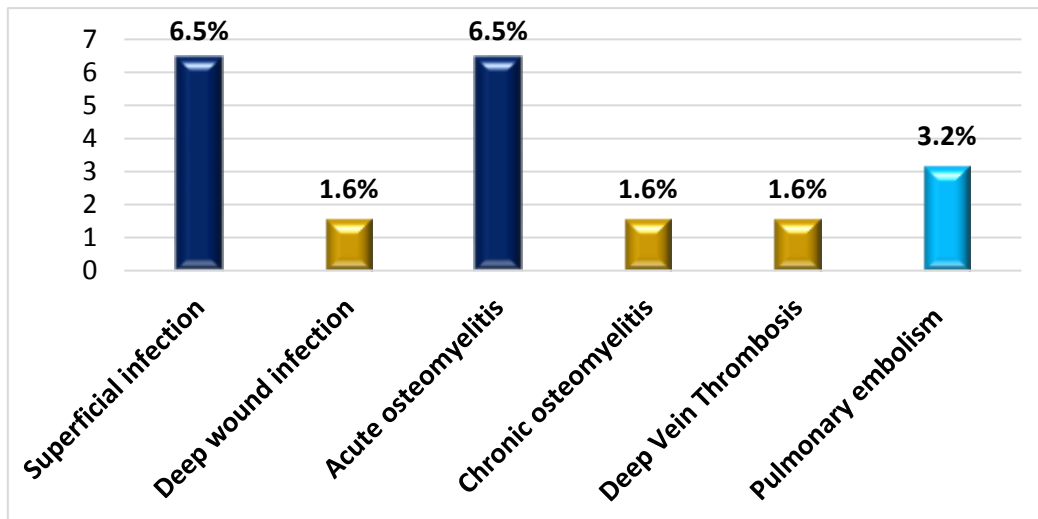


Figure 2: Distribution of complications among the study patients (n=62)

Unsatisfactory outcome of treatment procedure of femur open fractures was seen in 6 out of 62 patients, shortening in 1 (1.6%) patient, mal-union in 1 (1.6%) patient, non-union in 2 (3.2%) patients and stiffness found in 2 (3.2%) patients (Table 3 and Figure 3).

Table 3: Unsatisfactory outcome of femur open fractures treatment by interlocking nail

Variables	No	%
Shortening	Yes	1 1.6
	No	61 98.4
Mal-union	Yes	1 1.6
	No	61 98.4
Nonunion	Yes	2 3.2
	No	60 96.8
Stiffness	Yes	2 3.2
	No	60 96.8

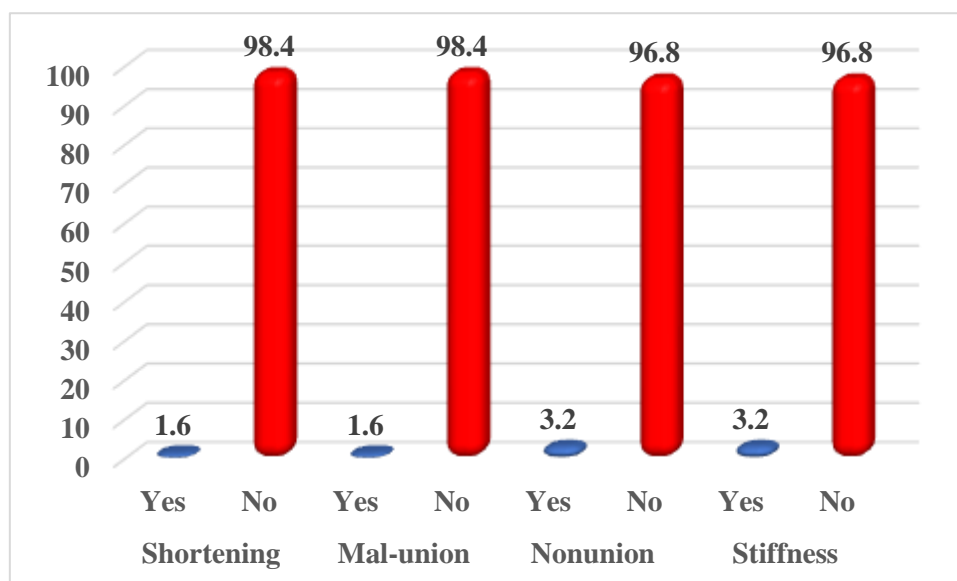


Figure 3: Unsatisfactory outcome of femur open fractures by interlocking nail

DISCUSSION

Femur is the most fractured long bone in the body that often necessitates surgical fixation [11]. Femoral shaft fractures have bimodal distribution across different age groups with high velocity injuries, which are more common among adult males, while low energy injuries tend to be more common in children and elderly females [12]. The demographic characteristics, severity and mechanism of injury and site of fracture influence the pattern, presentation, and management of femoral fractures [10,12]. The pattern of fracture varies owing to the direction of the force applied and the quantity of force absorbed during the trauma, and the aim of an early intervention is to get stable, anatomic fixation and to allow early mobilization [13]. There are various treatment options for femur fracture, such as conservative management, fixation with screw and plate, intramedullary nailing, open reduction and internal fixation, and external fixation [12]. Intramedullary nailing is the gold standard treatment for femoral shaft fractures in adult patients [14].

In our study, we found higher percentage (61.2%) of patients were in age group 21-35 years old followed by the age group \leq 20 years (27.5%). The low occurrence of injuries was among the age group $>$ 35 years old (11.3%).

Regarding the sex, our results are in concordance with many other reports, where the males were the most commonly injured [15-17].

Our results are in disagreement with what was found in Libya [18] where the age of the patients ranged between 16 to 55 years old with a mean age 32 years.

Ibeanusi et al [19] reported in their study from Nigeria that (72.5%) of the open femur fractures were seen in male patients whereas (27.5%) cases were in females given a male to female ratio of 2.6:1. They reported also, that the age distribution of the fractures shows that most of the fractures (30.8%) occurred in persons between the age group (21-30) years for both males and females. The age groups from 21 years to 50 years contributed about 60% of the fractures. Children less than ten years contributed 16.6% of the fractures while persons older

than 60 years particularly females contributed (4.6%) of the fractures.

The worldwide incidence of femoral shaft fractures ranges between 10 and 21 per 100,000 per year. Two percent of these are open fractures [20,21].

Femoral shaft fractures demonstrate a bimodal distribution. Men are more likely to sustain a fracture between the ages of 15 to 35 years, while women begin to show a steady increase starting at age 60 years [20,22].

In the current study, the most injuries were found in the left side with (67.8%) followed by the right side (32.2%).

Olasinde et al [15] from Nigeria reported similar to our findings. They mentioned that the fractures involved the right side in (38.7%) patients and left side in (61.3%) patients.

Dar et al [23] from India reported in their study that all the patients were males. The left femur was involved in (43.2%) and the right in (56.8%) patients, whereas Ibeanusi et al [19] reported that there was no major difference in the distribution of the fractures between the right and the left sides.

In the present study we found Gustilo open fracture type 3A were seen in (98.4%) patients but type 3B was in (1.6%). In addition, we found in our current study that the site of open femur fracture was mostly in mid shaft in 42 (67.8%) patients, whereas distal and proximal shaft fractures were in 11 (17.7%) and 9 (14.5%) patients respectively. Dar et al [23] also found that by using the Gustilo-Anderson classification, the types of injury were (65%) type IIIA, (30%) type IIIB and (5%) type IIIC. They found also (46%) were proximal one-third, (32%) were middle one-third and (22%) were distal one-third fractures.

Ibeanusi et al [19] mentioned in their study that the most of the fractures involved the

shaft of the femur (58.1%). The proximal femur and the distal femur contributed (16.5%) and (25.4%) respectively.

Kalande [24] reported in his study that (63.2%) of the open femoral fractures were in the distal third of the femur. In the study by Robinson et al [25] only (7%) of the open fractures were in the distal third of the femur thus it is a more common site than previously documented. These fractures in the distal femur have higher propensity to complicate due to tethering of the neurovascular bundle as it enters the popliteal fossa and their proximity to the joint. They thus pose a challenge in the best method of fracture stabilization.

External fixation [26] when used for distal third open femur fractures requires that the knee is spanned, making it likely to have stiffness and it also entails unnecessary surgery on the unaffected tibia.

In the current study, the delayed primary closure mostly was 1-7 days with (71.0%) followed by (24.2%) cases with delayed primary closure 8-14 days.

In the present study we found in (56.6%) of the cases the intervention of intramedullary nail was between 7 – 14 days followed by (27.4%) cases with intervention time of 15 – 21 days and (16.0%) cases with ≥ 22 days.

Kalande [24] mentioned in his study that all patients who had nailing immediately after debridement had an infection rate of (10.53%). This infection rate in open fracture is low and therefore nailing did not increase the risk of infection [27].

Kalande [24] did debridement and stabilization within 8 hours but infection rate was (10.53%) and this was mainly superficial infection. Only one patient had deep-seated infection, therefore meticulous debridement, gentle and careful tissue handling even with some delay (all patients who were included had surgery within 8 hours) does not

compromise outcome in open femoral fracture following internal fixation by nailing.

Ferracini et al [28] and Williams et al [29] showed delaying nailing did increase infection rate. It remained at less than 11.2%. Dar et al [23] found in their study the average delay to reach the hospital was 8.4 hours (range 2-16 hours) and average delay between external fixation and interlocking was 26.7 days (range 17-37 days). External fixation was converted to close interlocking intramedullary nail in all patients under fluoroscopic control. Published study in Libya reported that the interval between the injury and the surgery was 8-48 hours [18].

In the present study, mostly debridement was performed once in (82.4%) patients.

Regarding the treatment of open fracture femur injuries, Dar et al [23] reported their treatment for their patients as immediate irrigation and thorough soft tissue debridement followed by axial alignment and initial stabilization with external fixation on the day of admission. Vascular reconstruction and external fixation were done in a single setting in two patients. Patients were encouraged to perform active and passive assisted exercises in bed and ambulate as soon as possible without bearing any weight on the injured limb. Repeated debridements (1 to 5; average, 3), delayed primary closure, and skin and soft tissue reconstruction were done in the day care operation theater as required in each patient before definitive treatment. Meticulous pin site care and daily antiseptic dressings of the wounds were performed. In cases where wounds did not granulate satisfactorily, culture sensitivity was established and specific antibiotic therapy was instituted.

Burg et al [4] reported that standardized care for gunshot open fractures has been established in some centers in developed

countries. These include operative debridement of any devitalized soft tissue and bone fragment followed by copious irrigation and early fixation. The method of bone fixation is predicated on the pattern of fracture comminution, the generalized status of the patient and local soft tissue problems encountered.

In our study, we found out of 62 patients (16.1%) cases complicated by infections and (4.8%) cases of thrombosis. The infections were distributed as follows: Superficial infection was found in 4 (6.5%) patients, deep wound infection was found in one (1%) patient, and acute osteomyelitis was found in 4 (6.5%) patients.

In addition, the chronic osteomyelitis was found in (1.6%) patient. The other complications in our study were deep vein thrombosis in (1.6%) patients and pulmonary embolism in (3.2%) patients.

Regarding infection, Ferracini et al [28] from Brazil found in their study two patients in the IM nail patients presented deep infections (10%) and two superficial infections (10%). O'Brien et al [30] studied 63 open femoral fractures primarily treated with intramedullary locked milled nail with an infection rate of 12%.

Lowe et al [31] did nailing on 67 patients with open femoral fractures immediately after debridement. All healed within 4 months with an infection rate of less than 10%.

The unsatisfactory outcome of treatment procedure of femur open fractures in our study were shortening in (1.6%) patient, malunion in (1.6%) patient, non-union in (3.2%) patients and stiffness found in (1.6%) patient. Ali et al [6] mentioned in their study in Pakistan that 2 patients (2.94%) developed limb shortening of 2 cm.

Dealing with nonunion and malunion is challenging in femur fracture, and proper and

systematic follow-up is a key to deal with any delay union [14].

Report from Pakistan revealed that 4 patients (5.88%) got non-union [6] and our findings were less than that.

Ferracini et al [28] from Brazil reported in their study that union failure was found in one patient (2.7%) treated with IM nail. One fracture with delayed union evolved to cure after treating the superficial infection.

Lowe et al [31] did nailing on 67 patients with open femoral fractures immediately after debridement. All healed within 4 months with malunion rate of less than (2%). These finding and previous study finding are consistent to our study results.

Intramedullary nailing is the “gold standard” of treatment for adult femoral shaft fractures because only a short hospital stay is required and it allows an early active range of motion and weight-bearing [32].

The nonunion rate after failed Intramedullary nailing has been known to be low, ranging from 0.8 to 2% [33,34]. However, with increasing number of patients with femoral shaft fracture and widespread application of intramedullary nailing technique, the nonunion seem to be more common than predicted, with a range of 6.3–12.5% [35,36].

CONCLUSION

We concluded that, intramedullary nailing provides an effective device in patients with gunshot fractures of the femur. It is safe and effective and provides strong fixation, rotational stability and earliest return to functional status. Union of all fractures achieved with reduced complications. Further studies with large number of samples are in need.

REFERENCES

1. Crandon IW, Bruce CA, Harding HE. Civilian cranial gunshot wounds: a Jamaican

experience. *West Indian Med J.* 2004; 53: 248-251.

2. Mauffrey C. Management of gunshot wounds to the limbs: A review. *The Internet Journal of Orthopedic Surgery.* 2006; 3(1): 1-3
3. Stapley SA, Cannon LB. An overview of the pathophysiology of gunshot and blast injury with resuscitation guidelines. *Current Orthopaedics* 2006; 20: 322-332.
4. Burg A, Nachum G, Salai M, Havvi B, Heler S, Velkes S, et al. Treating civilian gunshot wounds to the extremities in a level 1 trauma center: our experience and recommendations. *Isr. Med. Assoc. J.* 2009; 11: 546-551
5. Wright DG, Levin JS, Esterhai JL, Heppenstall RB. Immediate internal fixation of low velocity gunshot-related femoral fractures. *J Trauma.* 1993; 35: 678-681.
6. Ali MA, Hussain SA, Khan MS. Evaluation of results of interlocking nails in femur fractures due to high velocity gunshot injuries. *J. Ayub Med. Coll. Abbottabad.* 2008; 20: 16-19.
7. Dougherty P.J, Vaidya R, Silverton CD, Bartlett CS, Najibi S. Joint and long-bone gunshot injuries. *Instr. Course Lect.* 2010; 59: 465-479.
8. Hao J, Cuellar DO, Herbert B, et al. Does the OTA open fracture classification predict the need for limb amputation? A retrospective observational cohort study on 512 patients. *J Orthop Trauma.* 2016; 30:194–198.
9. Haque MA, Hossain MZ, Kabir MH. Interlocking intramedullary nailing in fracture shaft of the femur. *Mymensingh Med J.* 2009; 18:159-64.
10. Alobaidi AS, Al-Hassani A, El-Menyar A, et al. Early and late intramedullary nailing of femur fracture: A single center experience. *Int J Crit Illn Inj Sci.* 2016; 6:143-147
11. Anyaehie U, Ejimofor O, Akpuaka F, et al. Pattern of femoral fractures and associated injuries in a Nigerian tertiary trauma centre. *Niger. J. Clin. Pr.* 2015; 18:462.

12. Khan AM, Tang QO, Spicer D. The Epidemiology of Adult Distal Femoral Shaft Fractures in a Central London Major Trauma Centre Over Five Years. *Open Orthop. J.* 2017;11:1277–1291.
13. Femur Injuries and Fractures. Available on: <https://emedicine.medscape.com/article/90779-overview>.
14. Yoon RS, Liporace FA. Impact of Intramedullary Nailing in the Treatment of Femur Fractures An Evolutionary Perspective. *Bull. Hosp. Jt. Dis.* 2018; 76:9–13.
15. Olasinde AA, Ogunlusi JD, Ikem IC. Outcomes of the treatment of gunshot fractures of lower extremities with interlocking nails. *SA Orthopaedic J.* 2012; 11(4): 48-51
16. Aderonmu AO, Fadiora SO, Adesunkanmi AR, et al. The pattern of gunshot injuries in a communal as seen in two Nigerian teaching hospitals. *J. Trauma* 2003;55:626-30.
17. Persad IJ, Reddy RS, Saunders MA, et al. Gunshot injuries to the extremities: experience of a UK trauma centre. *Injury* 2005;36: 407-11.
18. Hassan KM, Al-Kady RH, Attia AM, et al. Short term results of intramedullary nail in open femoral fracture in adult. *Zagazig University Medical Journal.* 2020; 26 (6): 997-1005
19. Ibeanusi SE, Chioma J. Pattern and Outcome of Femoral Fractures Treated in a Regional Trauma Centre in South Nigeria. *Int Arch Orthop Surg.* 2019; 1-9.
20. Weiss RJ, Montgomery SM, Al Dabbagh Z, et al. National data of 6409 Swedish inpatients with femoral shaft fractures: stable incidence between 1998 and 2004. *Injury.* 2009; 40(3):304-8.
21. Enninghorst N, McDougall D, Evans JA, et al. Population-based epidemiology of femur shaft fractures. *J Trauma Acute Care Surgery.* 2013; 74(6): 1516-1520
22. Singer BR, McLauchlan GJ, Robinson CM, et al.
23. of age and gender. *J Bone Joint Surg Br.* 1998; 80(2): 243-8.
24. Dar SRT, Kangoo KA, Dar FA, et al. External fixation followed by delayed interlocking intramedullary nailing in high velocity gunshot wounds of the femur. *Turkish Journal of Trauma & Emergency Surgery.* 2009; 15(6): 553-558
25. Kalande FM. Treatment outcomes of open femoral fractures at a country hospital in Nakuru. Kenya. *East African Orthopaedic Journal.* 2018; 12(2): 52-55
26. Robinson CM, Brown CM. Open fractures. *Musculoskeletal trauma series Femur, Arnold (A2) London abc.* 2002; 174 -175.
27. Singh D, Garg B, Bassi JT, et al. Open grade III fracture femur shaft. Outcome after early reamed intramedullary nailing. *Ortho Trauma Surg Res.* 2011; 97(5): 506-511.
28. Grosse A, Christie J. Open adult femoral fracture treated by early intramedullary nailing. *J Bone Joint Surg (Br).* 2006; 75-B: 562-565.
29. Ferracini AM, Faloppa F, Daltro GC, et al. Prospective and randomized study of patients with open fractures of the femoral shaft, treated with plate or open intramedullary locked nail. *Acta Ortop Bras.* 2008; 16(2):102-106.
30. Williams MM, Askins V, Hinkes EW, et al. Primary reamed intramedullary nailing of open femoral shaft fractures. *Clin Orthop Relat Res.* 1995; (318):182-90.
31. O'Brien PJ, Meek RN, Powell JN, et al. Primary intramedullary nailing of open femoral shaft fractures. *J Trauma.* 1991; 31:113-6.
32. Lowe DW, Hansen ST, et al. Immediate nailing of open fractures of the femoral shaft. *J Bone Joint Surg (Am).* 1988; 70-A: 812-820.
33. Rockwood C, Green D, Bucholz R. *Rockwood and Green's fractures in adults.* Philadelphia: Wolters Kluwer Health/Lippincott Williams & Wilkins; 2010.
34. Ma YG, Hu GL, Hu W, Liang F. Surgical factors contributing to nonunion in femoral shaft fracture following intramedullary nailing. *Chin J Traumatol.* 2016; 19:109–12.

35. Brumback RJ. The rationales of interlocking nailing of the femur, tibia, and humerus. Clin Orthop Relat Res. 1996; 324: 292–320.
36. Pihlajamaki HK, Salminen ST, Bostman OM. The treatment of nonunions following intramedullary nailing of femoral shaft fractures. J Orthop Trauma. 2002; 16:394–402.
37. Wolinsky PR, McCarty E, Shyr Y, et al. Reamed intramedullary nailing of the femur: 551 cases. J Trauma. 1999; 46:392–9.

How to cite this article: Omar Abdulsalam Abdullah Hadi Mohsen. Treatment of open femur fracture of the gunshot injuries by interlocking nail in Aden, Yemen. *International Journal of Science & Healthcare Research*. 2023; 8(2): 395-404.
DOI: <https://doi.org/10.52403/ijshr.20230250>
