

Evaluation of Cystoid Macular Edema in Patients with Retinal Vein Occlusion, Makkah Eye Hospital, Aden, Yemen

Reem Alkhadher Saleh¹, Ibtihal Aidroos Zain Gaffer²

^{1,2}Assistant Professor, Department of Special Surgery, Eye Unit Faculty of Medicine, University of Aden, Yemen

Corresponding Author: Dr. Reem Alkhadher Saleh

DOI: <https://doi.org/10.52403/ijshr.20230236>

ABSTRACT

Background: Cystoid macular edema (CMO) represents a common pathologic sequel of the retina. This study aimed to study the occurrence of cystoid macular edema in patients with retinal vein occlusion.

Materials and methods: We reviewed retrospectively the medical records of 54 retinal vein occlusion patients in Makkah eye hospital in Aden, from January to December 2021. The collected data analyzed by SPSS version 22. Chi-square test was used and a p-value less than 0.05 was determined as statistically significant.

Results: The total study patients with retinal vein occlusion (RVO) were 54, (males 63.0% and females 37.0%). The mean age was 58.2 ± 12.7 years. The most side involvement of branch retinal vein occlusions (BRVO) was in the right eyes with (25%) and of central retinal vein occlusions (CRVO) in (30%), ($p > 0.05$). The total number of eyes with RVO was 60 eyes, of which 26 eyes were with BRVO and 34 eyes with CRVO. In eyes with BRVO (35.0%) developed CMO while in eyes affected by CRVO, (31.7%), ($p < 0.05$). We found higher intra-ocular pressure (IOP) > 21 mmHg in CRVO with (18.4%) while in BRVO were in (8.3%), ($p > 0.05$). There was a positive correlation between hypertension and RVO ($P < 0.05$) and there was no significant relation in this study between glaucoma and occurrence of RVO ($p > 0.05$). The visual acuity after receiving the Avastin injections improved in all visual acuity groups.

Conclusion: In this study, males were predominant. The CRVO was the commonest

type of RVO. Some patients with CRVO and BRVO developed CMO. The relation between values of BRVO and CRVO related to the occurrence of CMO was statistically significant ($p < 0.05$).

Key words: Evaluation, cystoid macular edema, retinal vein occlusion, Aden, Yemen

INTRODUCTION

Cystoid macular edema (CMO) represents a common pathologic sequel of the retina and occurs in a variety of pathological conditions such as intraocular inflammation, central or branch retinal vein occlusion, diabetic retinopathy and most commonly following cataract extraction. Histological studies show that radially orientated cystoid spaces consisting of ophthalmoscopically clear fluid are often clinically detectable in the macula area. These cysts seem to be areas of retina in which the cells have been displaced [1].

Retinal diseases are emerging causes of visual impairment and blindness in the world and retinal vein occlusion (RVO) is the second most common retinal vascular diseases after diabetic retinopathy [2,3].

RVOs are divided into central retinal vein occlusion (CRVO), hemispheric retinal vein occlusion (HRVO), and branch retinal vein occlusions (BRVO). BRVO is a venous occlusion at any branch of the central retinal vein. Occlusions occurring at the proximal part of the central retinal vein trunk results

in an HRVO, which is considered a subtype of either CRVO or BRVO [4].

The retina has a dual blood supply, with retinal vessels supplying the inner retina, and choroidal vessels supplying the outer retina extending from the outer part of inner nuclear layer [5].

Retinal vein obstructions represent another common retinal vascular cause of CMO. In patients with central retinal vein occlusion or a tributary branch occlusion involving the macula, CMO is a major cause of visual loss. This edema, if severe or chronic (>8 months), causes permanent diminution of vision secondary to disruption of the microscopic intra-retinal connections and to the intracellular damage suffered by the visual elements [6]. CRVO is an acute retinal vascular condition that can severely affect visual acuity [7]. Previous studies estimated that ~2.5 million people worldwide are affected by CRVO and about 13.9 million people are affected by BRVO [8]. Visual loss after CRVO commonly occurs as a result of macular edema, macular ischemia, or in more advanced stages, vitreous hemorrhage, and neovascularization [9]. BRVO is the most common RVO with an incidence of 0.44%-1.6% [8]. A meta-analysis completed in 2010 by Rogers et al [8] pooled data from 11 studies from the United States, Europe, Asia and Australia with 49,869 subjects and found that the estimated prevalence of any RVO was 0.52%, BRVO was 0.442%, and CRVO was 0.08%.

MATERIALS AND METHODS

This study is a retrospective descriptive work in which we reviewed the medical records of 54 patients who diagnosed with retinal vein occlusion. We obtained the demographic data, medical history, results of physical examination of the eyes and some results of treatment procedures of all patients diagnosed with retinal vein occlusion in Makkah eye hospital from January to December 2021, and compared the findings with published results in other countries. CMO was diagnosed according to

the OCT results that was requested for all eyes affected by RVO. The patients with peak intra-ocular pressure (IOP) above 21 mmHg were designated as high-tension cases and those 21 mmHg and under, as normal-tension cases [10]. In addition, we categorized the levels of visual acuity as follows:

a) 0.4 – 0.6 (mild visual impairment), b) 0.2 – 0.3 (moderate visual impairment) and c) 0.05 – 0.1 (severe visual impairment) [11]

The collected data were analyzed by using the SPSS version 22. The data were shown as mean ± standard deviation for continuous variables. Categorical variables were presented in percentages. Independent t-tests were used to analyze continuous variables, while for categorical variables chi-square test was used to compare two groups and a p-value less than 0.05 was determined as statistically significant.

RESULTS

This retrospective study comprised 54 patients with RVO of which 34 (63.0%) were males and 20 (37.0%) female, with ratio male to female 1.7:1. The age of the patients ranged between 30 – 87 years and the mean age was 58.2 ± 12.7 years. The patients were divided into four age groups: 30 – 44 years 12 (22.2%) patients; 45 – 59 years 14 (25.9%) patients; 60 – 74 years 24 (44.5%) patients and ≥ 75 years 4 (7.4%) patients. Most of the patients were from urban governorates 31 (57.4%), as shown in Table 1 and Figure 1.

Table 1: Distribution of demographic variables of the RVO patients (n=54)

Variables	No	%
Sex:		
Males	34	63.0
Females	20	37.0
Ratio male to female:	1.7:1	
Range of age (years):	30 - 87	
Mean age:	58.2 ± 12.7	
Age groups:		
30 – 44	12	22.2
45 – 59	14	25.9
60 – 74	24	44.5
≥ 75	4	7.4
Residence:		
Urban	31	57.4
Rural	23	42.6

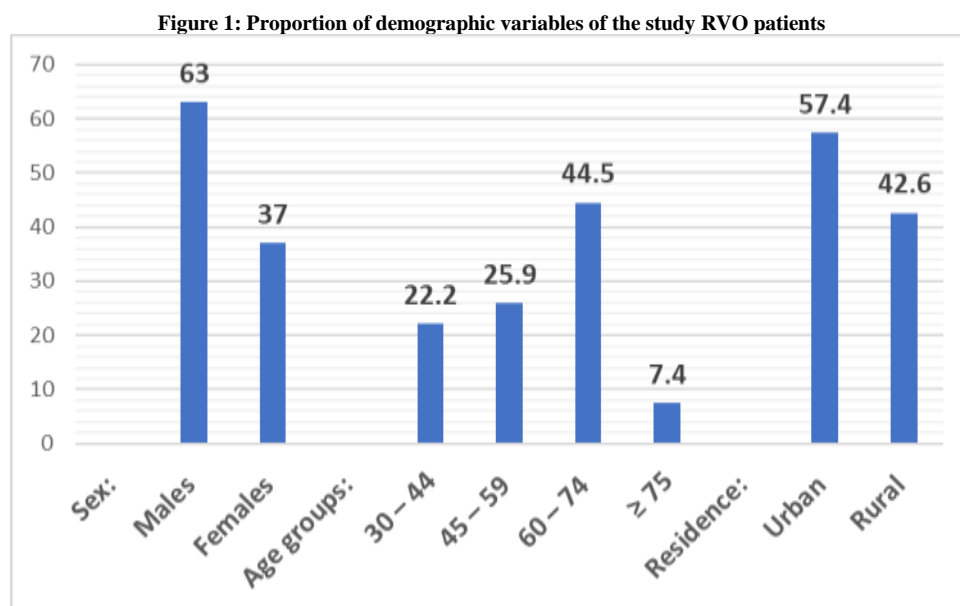


Table 2 showed the most side of involvement of BRVO was in the right eyes with 15 (25%) right eyes involved, and of CRVO in 18 (30%) right eyes. There is no statistical relation between values of BRVO and CRVO related to the side of involvement ($p > 0.05$).

In Table 2 we found the total number of eyes with BRVO were 26 (43.3%) and the CRVO were 34 (56.7%).

In eyes with BRVO 21 (35.0%) developed CMO while in eyes affected by CRVO, 19 (31.7%)

The relation between values of both BRVO and CRVO related to the occurrence of CMO was statistically significant ($p < 0.05$). The pre-treatment IOP were categorized in two groups: normal IOP ≤ 21 mmHg and higher IOP greater than 21 mm Hg.

We found higher intra-ocular pressure > 21 mmHg in CRVO with 11 (18.4%) while in BRVO were in 5 (8.3%), ($p > 0.05$).

Table 2: Relation between fundus findings and varies variables (n=60)

Variables	Fundus findings		Total	P-value
	BRVO No (%)	CRVO No (%)		
<i>Side involvement:</i>				
Left	11 (18.3)	16 (26.7)	26 (43.3)	0.459
Right	15 (25.0)	18 (30.0)	34 (56.7)	
<i>Subtotal</i>	26 (43.3)	34 (56.7)	60 (100)	
<i>OCT:</i>				
CMO	21 (35.0)	19 (31.7)	40 (66.7)	0.039
Free of CMO	5 (8.3)	15 (25.0)	20 (33.3)	
<i>Subtotal</i>	26 (43.3)	34 (56.7)	60 (100)	
<i>IOP:</i>				
≤ 21 mmHg	21 (35.0)	23 (38.3)	44 (73.3)	0.200
> 21 mmHg	5 (8.3)	11 (18.4)	16 (26.7)	
<i>Subtotal</i>	26 (43.3)	34 (56.7)	60 (100)	

BRVO = Branch retinal vein occlusion; CRVO = Central retinal vein occlusion; OCT = ocular coherence tomography; CMO = cystoid macula edema; IOP = intraocular pressure;

Thirty-eight (63.3%) eyes with CMO received intravitreal Avastin, while 22 (36.7%) eyes did not receive any, Table 3 and Figure 2.

Table 3: Frequency of eyes with CMO underwent Avastin injections.

Variables	No	%
<i>Intravitreal Avastin:</i>		
Yes	38	63.3
No	22	36.7
<i>Total</i>	60	100

Figure 2: Proportion of eyes with CMO underwent Avastin injections.

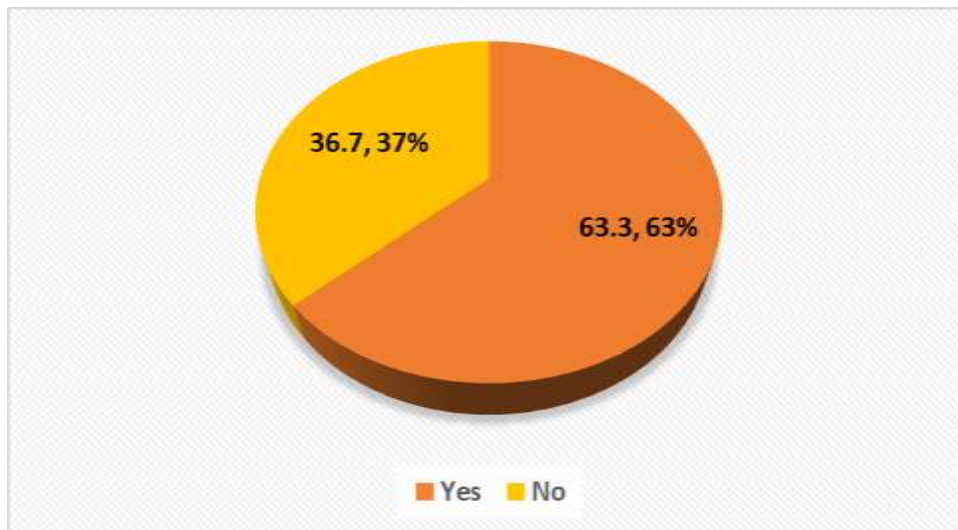


Table 4 showed the correlation between risk factors hypertension and glaucoma versus RVO.

We illustrated table 4 as follows: a) The hypertension was collected and calculated from the total study RVO patients (54patients). While glaucoma was collected and calculated from the total RVO eyes (60 eyes).

It appeared that hypertension was found in 9 (16.7%) BRVO cases and in 5 (9.3%) CRVO cases. There is positive correlation between hypertension and RVO ($P < 0.05$). Glaucoma was found in 7 (11.7%) eyes with BRVO and in 15(25.0%) eyes with CRVO. There was no statistically significant correlation between glaucoma and occurrence of RVO ($p > 0.05$).

Table 4: Correlation between risk factors hypertension and glaucoma versus RVO

Variables	RVO			Total No (%)	P-value
	BRVO No (%)	CRVO No (%)	None No (%)		
<i>Hypertension:</i>					
Yes	9 (16.7)	5 (9.3)	11 (20.4)	25 (46.4)	0.018
No	2 (3.7)	13 (24.1)	14 (25.9)	29 (53.6)	
Total	11 (20.4)	18 (33.3)	25 (46.3)	54 (100)	
<i>Glaucoma:</i>					
Yes	7 (11.7)	15 (25.0)	0 (0.0)	22 (36.7)	0.136
No	19 (31.7)	19 (31.7)	0 (0.0)	38 (63.3)	
Total	26 (43.3)	34 (56.7)	0 (0.0)	60 (100)	

RVO = Retinal vein occlusion; BRVO = Branch retinal vein occlusion; CRVO = Central retinal vein occlusion;

Table 5 showed the comparison between corrected VA and VA after Avastin injections. In the group of post corrected VA, we found the normal visual acuity of 0.7 – 1 was in 4 (6.8%) eyes. The visual acuity (mild visual impairment) of 0.4 – 0.6 found in 15 (25%) eyes. The visual acuity of 0.2 – 0.3 (moderate visual impairment) found in 9 (15%) eyes. Additionally, 12 eyes (20%) were in the 0.05 – 0.1 visual acuity group (severe visual impairment). Counting finger (CF) group were 18 eyes

(29.9%) , and hand movement (HM) group 2 eyes (3.3%).

Table 5 illustrated the visual acuity after receiving the Avastin injections. We observed the improvement of visual acuity in each group. The group of visual acuity 0.7 – 1 increased to 6 (10.1%). In the group 0.4 – 0.6 (mild visual impairment) decreased to 7 (11.6%) and in rest of the groups we observed decrease in values. The improvement is evident in all groups after Avastin injections.

Table 5: Corrected VA and post intravitreal Avastin treatment of eyes with CMO due to RVO (n = 60 eyes).

Variables	Corrected VA		VA after Avastin	
	Eyes No	(%)	Eyes No	(%)
Visual acuity:				
0.7 – 1.0	4	(6.8)	6	(10.1)
0.4 – 0.6 (mild VI)	15	(25.0)	7	(11.6)
0.2 – 0.3 (Mod VI)	9	(15.0)	4	(6.7)
0.05 – 0.1 (severe VI)	12	(20.0)	5	(8.3)
Counting finger	18	(29.9)	11	(18.3)
Hand movement	2	(3.3)	1	(1.7)
Improvement	0	(0.0)	26	(43.3)
Total	60	(100)	60	(100)

VI = Visual impairment; Mod VI = Moderate visual impairment

DISCUSSION

RVO are a heterogeneous group of disorders that have in common impaired venous return from the retinal circulation. Classification of RVO can be broken down into BRVO, HRVO, and CRVO depending on the site of the obstruction. If the occlusion occurs within or posterior to the optic nerve head, it is labeled CRVO, occlusion at the major bifurcation is determined to be a HRVO, and any obstruction within a tributary is a BRVO. Often, HRVO is considered as a separate condition that behaves intermediately between BRVO and CRVO [12,13]. Although all retinal vein occlusions share commonalities in many clinical features, they are distinct clinical entities in their risk factors, prognosis, and even occasionally, treatment. Even within each disease process, a spectrum of severity exists such that some patients can be completely asymptomatic and others can lose light perception. Treatment from appropriate expertise reduces the likelihood of blinding disease but does not eliminate it as a possibility [14].

The most common visually threatening complication of retinal vein occlusion is cystoid macular edema. Several landmark trials provide guidance in improving visual outcomes compared with the natural history for people with both BRVO and CRVO. In general, baseline visual acuity is predictive of out-comes when no therapy is delivered. The presence of an APD and extent of capillary nonperfusion further influence likelihood of vision loss in the BVOS and CVOS [15,16].

In the present study, there were 54 patients of which (63.0%) were males and (37.0%) were females. The age of the patients ranged between 30 – 87 years and the mean age was 58.2 ± 12.7 years.

Patients of the age group 60 – 74 years were predominant with (44.5%). Zhang et al [17] reported similar findings to our study results, the male patients were (57.7%) while the female patients were (42.3%) and the mean age of the patients was 57.70 ± 12.91 years.

In the present study, the most side involvement of RVO was in the right side with 15 (25%) BRVO in right eyes and 18 (30%) CRVO in right eyes.

There was no statistical relation between values of BRVO and CRVO related to side involvements ($p > 0.05$).

In Table 2 we found the total number of eyes with BRVO were 26 (43.3%) and the CRVO were 34 (56.7%). The CRVO was the commonest type of RVO with (30.0%) in the right eyes and (26.7%) in the left eyes. The higher rate of CRVO in our study may be attributed to the significant visual impairment it causes that force the patient to seek a medical treatment and visit an eye clinic. However, may be a lot of patients with BRVO did not need to visit an eye clinic as the RVO might be far away of the macular area so they could be accidentally diagnosed during routine eye examination.

Some studies showed a higher proportion of BRVO patients older than 65 at the onset of the disease compared to CRVO [18], but others found no significance of age in the distribution of CRVO and BRVO [19].

Laouri et al [20] reported in their published study, that retinal vein occlusion includes

CRVO and BRVO. They added the prevalence of CRVO is 0.1 to 0.2%. BRVO is more common than CRVO and the prevalence of BRVO is 0.5 to 2.0%.

We observed in the study that BRVO occurred less than CRVO it was (25.0%) in the right eyes and (18.3%) in the left eyes.

The incidence of BRVO is generally higher than the incidence of CRVO. In the United States, the 5-year incidence of BRVO was 0.6% and the incidence of CRVO was 0.2% at 15 years the incidences were 1.8 and 0.5%, respectively [21,22]. In Australia, about three times as many individuals developed BRVO than CRVO over 10 years [23].

However, a hospital based study done in Nepal showed BRVO (70%) to be more common than CRVO (26.6%) [24]. Other population based studies done in Korea, Australia and central India showed the prevalence of BRVO to be 63.4%, 69.5% and 85.7 % respectively [2,25,26].

Retinal vein occlusion is an obstruction of the retinal venous system that may involve the central retinal vein or a branch retinal vein [27]. In the vast majority of cases, BRVO occurs at arteriovenous crossing sites where the artery is positioned anterior to the vein [28].

Cystoid macular oedema (CMO) is the most common cause of vision loss in patients with central retinal vein occlusion (CRVO) [29,30]. Without treatment, CMO will resolve in only 30% of patients with non-ischaemic CRVO and less with ischaemic CRVO [30].

Surprisingly, In the present study, we found that 21 eyes with BRVO (35.0%) developed CMO while 19 (31.7%) eyes with CRVO developed CMO. It is clearly in this study that the rate of CMO in BRVO is higher than in CRVO with results that are opposite to what was found elsewhere. May be most of the eyes in the study with CRVO are of non – ischaemic type and lately presented in the eye clinic after the spontaneous resolve of CMO took place. However, unusual higher CMO rate in BRVO in our study could be explained by

the possibility of an ischaemic type of BRVO and the site involving the macular area. We cannot explain those results for sure as FFA (fundus fluorescein angiography) was not done to distinguish whether it was an ischaemic or non-ischaemic RVO.

The relation between values of BRVO and CRVO related to the occurrence of CMO was statistically significant ($p < 0.05$).

Untreated RVO often results in vision impairment and significant ocular complications in a substantial proportion of patients [30,31]. Some patients with CRVO develop macular edema, and approximately 5–15% of eyes with BRVO develop macular edema over 1 year [20].

In the current study, the pre-treatment IOP were categorized in two groups: normal IOP ≤ 21 mmHg and higher IOP greater than 21 mm Hg. We found higher intra-ocular pressure > 21 mmHg in CRVO with (18.4%) while in BRVO were in (8.3%), ($p > 0.05$).

Some published studies reported that CRVO has been shown to be associated with raised intraocular pressure [32,33] but their role in BRVO is less clear [20]. In the present study (63.3%) eyes received intravitreal Avastin and (36.7%) not received.

A small, retrospective review of 16 eyes of 15 patients with macular edema secondary to central retinal vein occlusion recently reported the short-term anatomic and visual acuity outcomes after treatment with intravitreal Avastin [34].

In a recent study, [35] showed that 3 months after the intravitreal use of Avastin, the electrical activity of the fovea and perifovea increased significantly. Improvements in drug delivery will be necessary in order to avoid repeated intravitreal injections and the cumulative risk of endophthalmitis associated with this route of administration [1].

In our present study, it appeared that hypertension was found in (16.7%) BRVO cases and in (9.3%) CRVO cases. There is a positive correlation between hypertension and RVO ($P < 0.05$).

Glaucoma was found in (11.7%) BRVO and in CRVO there were (25.0%). There was no positive correlation between glaucoma and occurrence of RVO ($p > 0.05$).

Hypertension has been identified as a risk factor for RVO in several studies, including the Beijing Eye Study [36], Beaver Dam Eye Study [21], and Blue Mountains Eye Study [23]. To date, the pathophysiology of RVO and hypertension has not been fully described, although several mechanisms have been proposed. First, elevated blood pressure can directly damage the retinal blood vessels causing hemorrhages, cotton wool spots, and macular edema [37].

Second, systemic hypertension has been demonstrated to adversely affect the ocular structure in various hypertensive eye diseases [38].

Al-Nawaiseh et al [39] reported in their published study that hypertension was more frequent in BRVO than in CRVO or in control group (53.8% vs. 40.9% and 29.2%). It was significantly associated with BRVO (p -value < 0.01). Al-Nawaiseh et al [39] found glaucoma to be significantly associated with CRVO ($p < 0.01$).

In our study, we compared between corrected VA and VA after Avastin injections.

We found the improvement of visual acuity in each group. The group of visual acuity 0.7-1 increased to (10.1%). In the group 0.4-0.6 (mild visual impairment) decreased to (11.6%) and in rest of the groups we observed decrease in values. The improvement is evident in all groups after Avastin injections.

Rosenfeld et al [40] mentioned that in May 2005 at the Bascom Palmer Eye Institute, University of Miami, USA, Avastin (bevacizumab) was first injected into the vitreous of an eye with macular edema from CRVO. A number of recent studies have shown promising short-term effects of Avastin when used for CME associated with BRVO or CRVO [34,35].

Conclusion: In this study of retinal vein occlusion (RVO) males were predominant and most of them were in the age group 60 –

74 years. The central retinal vein occlusions (CRVO) were the commonest type of RVO. Some patients with CRVO and BRVO developed cystoid macular edema. The relation between values of BRVO and CRVO related to the occurrence of CMO was statistically significant ($p < 0.05$). Further studies of the incidence, prevalence and treatment procedures of RVO are important and in need.

Declaration by Authors

Ethical Approval: Approved

Acknowledgement: None

Source of Funding: None

Conflict of Interest: The authors declare no conflict of interest.

REFERENCES

1. Rotsos TG, Moschos MM. Cystoid macular edema. Clin Ophthalmol. 2008; 2(4): 919-930.
2. Shin YU, Cho H, Kim JM, Bae K, Kang Mh, Shin JP, et al. Prevalence and associated factors of retinal vein occlusion in the Korean National Health and Nutritional Examination Survey, 2008–2012: A cross-sectional observational study. Medicine. 2016; 95(44):e5185.
3. Uhumwangho OM, Oronsaye D. Retinal Vein Occlusion in Benin City, Nigeria. Nigerian Journal of Surgery : Official publication of the Nigerian Surgical Research Society. 2016; 22(1): 17-20.
4. Niral K. Retinal vein occlusion: pathophysiology and treatment options. Clin Ophthalmol. 2010; 4: 809-816.
5. Jaulim A, Ahmed B, Khanam T, Chatziralli IP. Branch retinal vein occlusion: epidemiology, pathogenesis, risk factors, clinical features, diagnosis, and complications. An update of the literature. Retina. 2013; 33(5):901–91.
6. Coscas G, Gaudric A. Natural course of nonaphakic cystoid macular edema. Surv Ophthalmol. 1984; 28(Suppl): 471–84.
7. Hayreh SS. Prevalent misconceptions about acute retinal vascular occlusive disorders. Prog Retin Eye Res 2005; 24(4): 493–519.
8. Rogers S, McIntosh RL, Cheung N, Lim L, Wang JJ, Mitchell P et al. The prevalence of retinal vein occlusion: pooled data from population studies from the United States,

- Europe, Asia, and Australia. *Ophthalmology* 2010; 117(2): 313–319 e311.
9. Campochiaro PA, Hafiz G, Shah SM, Nguyen QD, Ying H, Do DV et al. Ranibizumab for macular edema due to retinal vein occlusions: implication of VEGF as a critical stimulator. *Mol Ther*. 2008; 16(4): 791–799.
 10. Hangqi Shen, Hui Zhang, Wei Gong, Tianwei Qian, Tianyu Cheng, Li Jin, et al. Prevalence, Causes, and Factors Associated with Visual Impairment in a Chinese Elderly Population: The Rugao Longevity and Aging Study. *Clin Interv Aging*. 2021; 16: 985-996.
 11. GBD 2019 Blindness and Vision Impairment Collaborators; Vision Loss Expert Group of the Global Burden of Disease Study. Causes of blindness and vision impairment in 2020 and trends over 30 years, and prevalence of avoidable blindness in relation to VISION 2020: the Right to Sight: an analysis for the Global Burden of Disease Study. *Lancet Glob Health*. 2021; 9(2):e144-e160.
 12. Scott IU, VanVeldhuisen PC, Ip MS, et al. Effect of bevacizumab vs aflibercept on visual acuity among patients with macular edema due to central retinal vein occlusion: the SCORE2 randomized clinical trial. *JAMA*. 2017;317:2072–2087.
 13. Scott IU, VanVeldhuisen PC, Oden NL, et al. Baseline characteristics and response to treatment of participants with hemiretinal compared with branch retinal or central retinal vein occlusion in the Standard Care vs Corticosteroid for Retinal Vein Occlusion (SCORE) study: SCORE study report 14. *Arch Ophthalmol*. 2012;130: 1517–1524.
 14. Ip M, and Hendrick A. Retinal Vein Occlusion Review. *Asia-Pac J Ophthalmol*. 2018;7: 40–45.
 15. Argon laser scatter photocoagulation for prevention of neovascularization and vitreous hemorrhage in branch vein occlusion. A randomized clinical trial. Branch Vein Occlusion Study Group. *Arch Ophthalmol*. 1986;104:34–41.
 16. Clarkson JG. Evaluation of grid pattern photocoagulation for macular edema in central vein occlusion. The Central Vein Occlusion Study Group M report. *Ophthalmology*. 1995;102:1425–1433.
 17. Zhang, Q., Hou, Y., Cao, X. et al. Predictors of visual recovery in patients with macular edema secondary to central retinal vein occlusion after treatment with Conbercept. *BMC Ophthalmol*. 2021; 21: 402
 18. Glacet-Bernard A, Coscas G, Chabanel A, Zourdani A, Lelong F, Samama MM. Prognostic factors for retinal vein occlusion: Prospective study of 175 cases. *Ophthalmology*. 1996;103: 551–560.
 19. Rath EZ, Frank RN, Shin DH, Kim C. Risk factors for retinal vein occlusions. A case-control study. *Ophthalmology*. 1992; 99: 509–514.
 20. Laouri M, Chen E, Looman M, Gallagher M. The burden of disease of retinal vein occlusion: Review of the literature. *Eye*. 2011; 25: 981–988.
 21. Klein R, Klein BE, Moss SE, Meuer SM. The epidemiology of retinal vein occlusion: the Beaver Dam Eye Study. *Trans Am Ophthalmol Soc*. 2000; 98: 133–141.
 22. Klein R, Moss SE, Meuer SM, Klein BE. The 15-year cumulative incidence of retinal vein occlusion: the Beaver Dam Eye Study. *Arch Ophthalmol*. 2008;126 (4):513–518.
 23. Cugati S, Wang JJ, Rochtchina E, Mitchell P. Ten-year incidence of retinal vein occlusion in an older population: the Blue Mountains Eye Study. *Arch Ophthalmol*. 2006; 124 (5): 726–732.
 24. Kolar P. Risk factors for central and branch retinal vein occlusion: a meta-analysis of published clinical data. *Journal of Ophthalmology*. 2014;2014:724780.
 25. Mitchell P, Smith W, Chang A. Prevalence and associations of retinal vein occlusion in Australia: The blue mountains eye study. *Archives of ophthalmology*. 1996;114(10): 1243-7.
 26. Jonas JB, Nangia V, Khare A, Sinha A, Lambat S. Prevalence and associations of retinal vein occlusions: the Central India Eye and Medical Study. *Retina (Philadelphia, Pa)*. 2013;33(1):152-9.
 27. Rehak M., Wiedemann P. Retinal vein thrombosis: pathogenesis and management. *J Thromb Haemost*. 2010; 8: 1886-94.
 28. Christoffersen N.L., Larsen M. Pathophysiology and hemodynamics of branch retinal vein occlusion *Ophthalmology*. 1999; 106: 2054-62.

29. Hayreh SS, Podhajsky PA, Zimmerman MB. Natural History of Visual Outcome in Central Retinal Vein Occlusion. *Ophthalmology*. 2011;118:119–33.e2.
30. McIntosh RL, Rogers SL, Lim L, et al. Natural history of central retinal vein occlusion: an evidence-based systematic review. *Ophthalmology*. 2010;117:1113–23.e15.
31. Rogers S.L., McIntosh R.L., Lim L., Mitchell P., Cheung N., Kowalski J.W., Nguyen H.P., Wang J.J., Wong T.Y. Natural history of branch retinal vein occlusion: an evidence-based systematic review. *Ophthalmology*. 2010; 117: e5
32. The Eye Disease Case-control Study Group. Risk factors for central retinal vein occlusion. *Arch Ophthalmol*. 1996; 114:545–54.
33. Frucht J, Shapiro A, Merin S. Intraocular pressure in retinal vein occlusion. *Br J ophthalmol* 1984;68:26–8.
34. Iturralde D, Spaide RF, Meyerle CB, et al. Intravitreal bevacizumab (Avastin) treatment of macular edema in central retinal vein occlusion: a short-term study. *Retina*. 2006; 26:279–84.
35. Moschos MM, Moschos MN. Intravitreal bevacizumab for macular edema due to CRVO. A multifocal-ERG and OCT study. *Doc Ophthalmol*. 2008; 116:147–52.
36. Zhou JQ, Xu L, Wang S, et al. The 10-year incidence and risk factors of retinal vein occlusion: the Beijing eye study. *Ophthalmology* 2013;120:803–8.
37. Kida T, Morishita S, Kakurai K, Suzuki H, Oku H, Ikeda T. Treatment of systemic hypertension is important for improvement of macular edema associated with retinal vein occlusion. *Clin Ophthalmol (Auckland, NZ)* 2014;8:955–8.
38. Katsi V, Marketou M, Vlachopoulos C, et al. Impact of arterial hypertension on the eye. *Curr Hypertens Rep* 2012;14:581–90.
39. Al-Nawaiseh Bassam, Al-Madani Mousa. Risk Factors for Central and Branch Retinal Vein Occlusion. *Middle East Journal for Family Medicine*. 2006; 4(2): 1-6
40. Rosenfeld P.J., Fung A.E., Puliafito C.A. Optical coherence tomography findings after an intravitreal injection of bevacizumab (avastin) for macular edema from central retinal vein occlusion. *Ophthalm. Surg. Lasers Imaging*. 2005;36:336–339.

How to cite this article: Reem Alkhadher Saleh, Ibtihal Aidroos Zain Gaffer. Evaluation of cystoid macular edema in patients with retinal vein occlusion, Makkah Eye Hospital, Aden, Yemen. *International Journal of Science & Healthcare Research*. 2023; 8(2): 288-296. DOI: <https://doi.org/10.52403/ijshr.20230236>
