

# Full Mouth Rehabilitation of Paediatric Patient with Early Childhood Caries - A Case Report

Tarang Tyagi<sup>1</sup>, Dinesh Rao<sup>2</sup>, Sunil Panwar<sup>3</sup>, Safna Ameen<sup>4</sup>

<sup>1</sup>Postgraduate Student, Department of Pediatric Dentistry, Pacific Dental College & Hospital  
Udaipur-313 024, Rajasthan State, India

<sup>2</sup>Professor and Head, Department of Pediatric Dentistry, Pacific Dental College & Hospital  
Udaipur-313 024, Rajasthan State, India

<sup>3</sup>Professor, Department of Pediatric Dentistry, Pacific Dental College & Hospital  
Udaipur-313 024, Rajasthan State, India

<sup>4</sup>Senior Lecturer, Department of Pediatric Dentistry, Pacific Dental College & Hospital  
Udaipur-313 024, Rajasthan, India

Corresponding Author: TarangTyagi

## ABSTRACT

Early childhood caries is a major global health issue that affects the oral health of infants and children negatively. Therefore, it should be addressed in the primitive stages. Silver diamine fluoride is a material that is effective in arresting the dental caries progression and thus, it is useful in halting the spread of the disease. Esthetic management of grossly decayed primary maxillary anterior teeth requiring full coronal coverage restoration is usually challenging to the pediatric dentists especially in young children. Over the years, many esthetic options have been used with each having its own advantages, disadvantages and associated technical, functional and esthetic limitations. Zirconia crowns have been used as a treatment alternative to address the esthetic concerns and ease of placement of extra-coronal restorations on primary anterior teeth. The present article presents a case where grossly decayed maxillary primary incisors were treated endodontically and restored esthetically and functionally with preformed zirconia crowns. Dealing with esthetic needs in children with extensive loss of tooth structure, using zirconia crowns would be practical and successful. The treatment described is simple and effective; it represents a promising alternative for rehabilitation of decayed primary teeth.

**Key words:** Esthetics, zirconia crowns, silver diamond fluoride, full mouth rehabilitation, silver fluoride bullet, fibre post

## INTRODUCTION

Early childhood caries means the severe destruction and premature loss of primary teeth due to caries. It is found more commonly in the children below the age of 6 years. They are progressive, rampant and acute in nature of progression.<sup>[1]</sup> Early childhood caries is a global oral health problem that continues to affect infants and preschool children.<sup>[2]</sup> The aesthetic appearance of the children are nowadays a social concern for the family and if the problem is not treated than it can result in a local, psychological, social and aesthetics problems. Hence, it is necessary to treat the early childhood caries.<sup>[1,3]</sup>

The treatment of traumatized, decayed and deformed deciduous teeth specially the anterior ones is often challenging because of their smaller size, thin enamel layer and also a close proximity of pulp to the tooth surface.<sup>[4]</sup> In an era of prevention, where the primary focus is on prevention of extension rather than an extension for prevention, the solution lies in silver diamond fluoride hypothesized potential to terminate the caries process and simultaneously prevent the formation of new dental caries.<sup>[5]</sup> Therefore, SDF has been labeled to be a “silver fluoride bullet.”<sup>[6]</sup>

There are different treatments options like faceted steel crowns, composite resin and poly carbonate crown for deciduous teeth specially the anterior teeth that are affected by the carious lesions. Nowadays there are aesthetics perceptions in the children for their teeth, so it is necessary to maintain the colour, shape and texture of the anterior deciduous maxillary teeth. Because of the decayed or absent teeth child experience various functional implications related to it such as pain, difficulty in speaking and swallowing.<sup>[7]</sup>

In the last past decades, there has been immense advancement in the technologies of the dental materials for the use in children. This has lead to constant need of new treatment techniques and also need to re-evaluate the treatment of philosophy of children. Over the last decade, keeping in mind the esthetic requirement of pediatric population preformed zirconia crowns for primary anterior teeth have been introduced.<sup>[4]</sup> In the

era of prevention, SDF can serve as an effective material in caries arresting and prevention; also in minimal intervention strategies where tooth coloured restorative materials can mask the discolouration.<sup>[8]</sup> The purpose of this article was to describe the rehabilitation of decayed deciduous teeth in a four year old boy using prefabricated zirconia crowns and silver diamond fluoride to arrest the dental caries progression.

## CASE REPORT

A 4-year old child accompanied by his parents presented to the department of the paediatric and preventive dentistry with the chief complaint of the multiple decayed teeth. Intra-oral examination revealed poor oral hygiene and multiple carious teeth. In the deciduous maxillary incisors the crowns were grossly decayed. Deep dental caries was present in relation to 51,52,54,61,62,64 and moderate dental caries in relation to 55,65,74,75,84,85. (Figure 1)

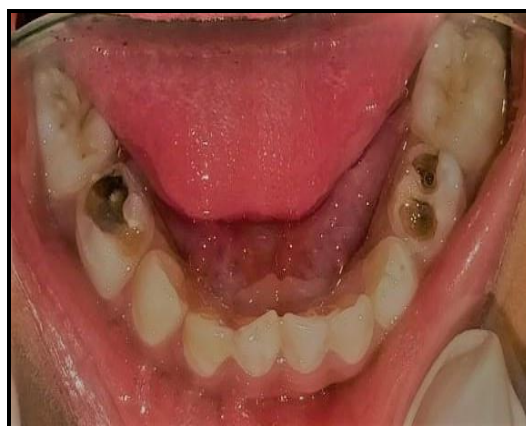
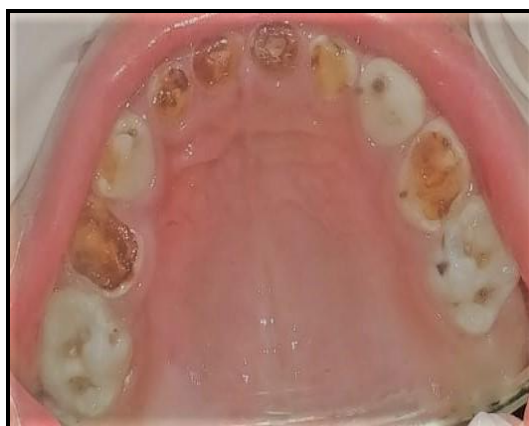
Figure 1 : Pre treatment intraoral photographs

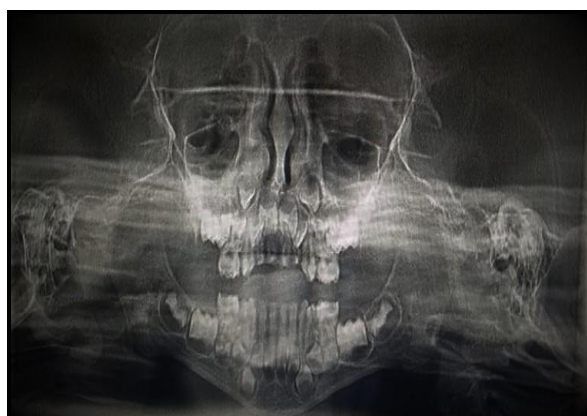

Figure 2: pre treatment OPG

The radiographic evaluation stated that there was absence of any pathological defects in the periapical area. The OPG did not showed any evidence of the defect in periodontal ligament space and alveolar bone. The radiological diagnosis stated that there was pulpal involvement of 51,52,61, 62,54,64.(Figure 2) Medical history was non-contributory. Also there was no significant history of parafunctional habit or bruxism. The complete treatment plan included silver diamond fluoride application

as its property to discoloured the teeth followed by restoration of carious teeth and pulpectomy followed by fibre post and core and crowns of destructed coronal portion of maxillary anterior teeth. Zirconia crowns were planned keeping in mind the esthetic concerns of the child and parents. The whole treatment plan was discussed with parents. Diet analysis and counselling was done and prophylaxis was carried out. The

child was cooperative and good behaviour praised at every visit. During the progressive visit the Tell, Show and Do model was used to introduce the instrument used for the treatment and oral prophylaxis. As the child was having the first dental visit to the clinics, the initial appointments were non-invasive and to develop the effective communications with the child.

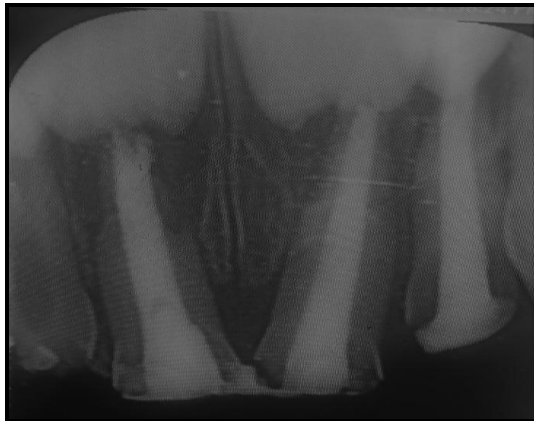


Figure 3: Radiographic representation of obturation with endoglas irt 51,52,61,54

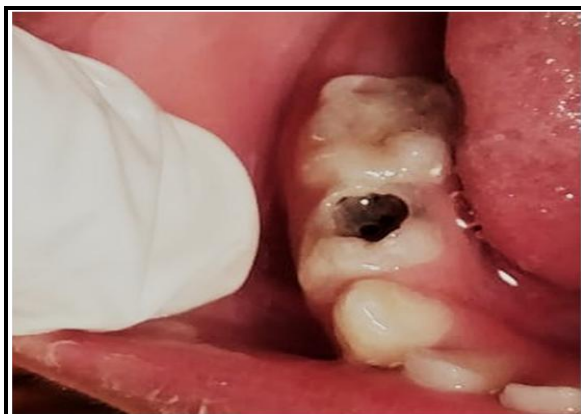
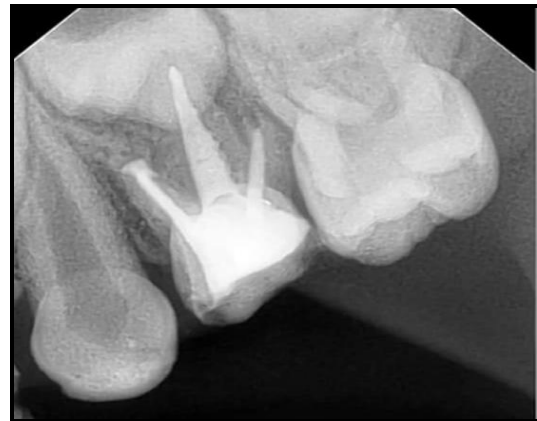
Figure 4: SDF application

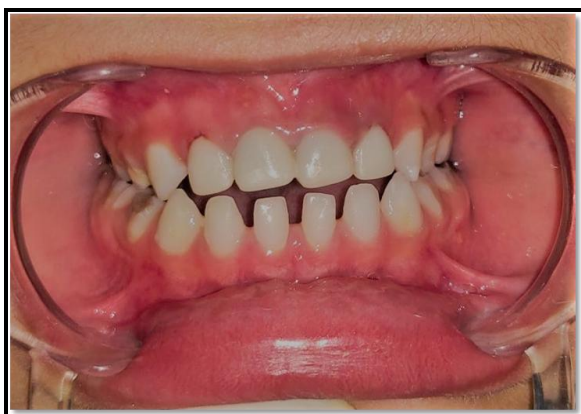

Figure 5 : Zirconia crowns irt 51,52,61,62; Post treatment intraoral photographs

At next visit, the pulp therapy was initiated irt 51,61,62,64 and caries excavation was done followed by 38% of SDF application irt 74,75,65 and GIC restoration. Third visit treatment, the cleaning and shaping and obturation was done using Endoflas using lentulospirals in relation to 51,61,62,64. (Figure 3) Pulp therapy was initiated in relation to 54 and caries excavation was done followed by 38% of SDF application irt 84,55. (Figure 4) Indirect pulp capping using Dycal application was done irt 85.

At fourth visit, obturation using Endoflas using lentulospirals and post endo restoration was done irt 54 and post space was created irt to 51,61 and 62; the fibre post was placed and core was build up. Composite build up was done irt 51,52,61 and 62.

During the next visit, zirconia crowns were used to build up the teeth. Zirconia crown sizes were selected by placing the incisal edge of the zirconia crown against the incisal edge of the tooth. After application of local anaesthesia jelly,

the tooth structure was cut for “passive fit” as the zirconia crowns do not flex. Teeth were then prepared using a tapered diamond bur in a high-speed handpiece. The length of the crown was first reduced incisally by 2 mm. For the labial surface, the 2-plane reduction was made close to natural tooth and the distance to the adjacent teeth was considered for proximal surface and parallel mesial and distal walls were prepared extending 1-2 mm subgingivally. Enough reduction of cingulum was done on the palatal surface. Feather-edge margins were prepared, about 1-2 mm subgingivally.

Marginal fit of the crowns was evaluated, after that the zirconia crowns were cemented with light cure resin cement (Rely X/3M ESPE) and were held with firm consistent pressure on the teeth at proper position till the initial set. The occlusion was checked and removal of interferences and shape modification required was done with high speed diamond bur. (Figure 5) The child and parents were instructed about the importance of oral hygiene and diet. They were also motivated to maintain regular recall appointments every 3 months. (Figure 6)

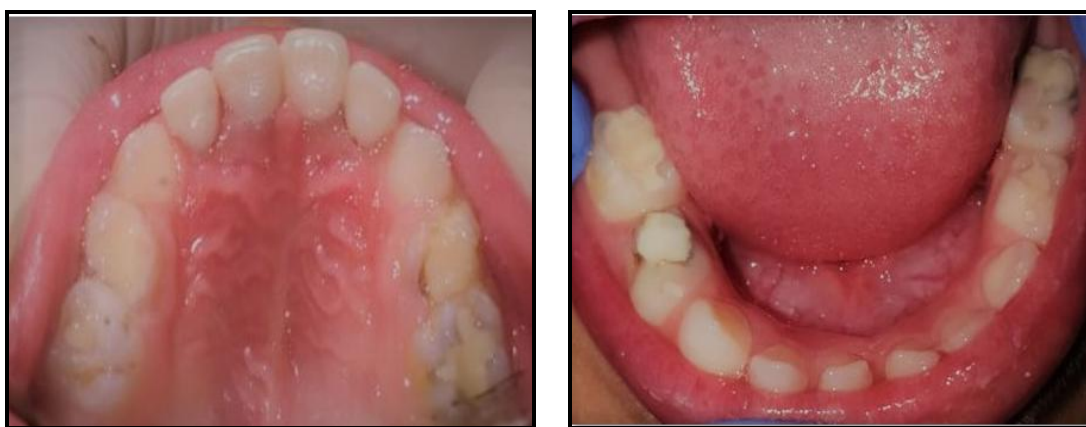

Figure 6: Post treatment after 3 months intraoral photograph

## DISCUSSION

Even with all the oral health prevention policies, dental caries remains prevalent in the preschool population, especially in children from low-income families, resulting in the need for intervention by the dental professional and public health policies. Primary teeth play a key role in phonetics, eating, aesthetics and maintaining space for permanent teeth. Thus, pediatric dentistry should invest efforts to keep these dental elements healthy until the time of their rhizolysis and exfoliation. [9,10] Despite attempts to improve the dental health and to minimize the effects of caries, pediatric dentists still deal with cases of extensive destruction of primary teeth. One of the most challenging tasks for the pediatric dentists is to restore grossly decayed primary anterior teeth with full coverage restorations which are durable esthetic and retentive. [11]

The permanent successor's development and eruption get altered when an anterior primary teeth is lost earlier than normal exfoliation time which results into increased arch length discrepancy, raising the potential for developing malocclusion at a later stage. The space should be maintained as early as possible. Most commonly at the age of 2 to 4 years because of ECC and/or trauma the primary incisors get destructed fully or partially. The lost at this age may results into psychological disturbances and affects the child self-esteem and socialization during an important phase of development, especially if these defects are visible during speech and laughter. [12,13]

In the present case the child was having grossly decayed maxillary anterior teeth, where as the caries were present on the occlusal surface of the posterior teeth of maxilla and mandible. The grossly decayed

teeth were treated with pulp therapy followed by fibre post and core for the crown build up. Caries were removed from the occlusal surface and SDF application was done followed by restoration with glass ionomer cement. The usage of SDF can be encouraged for the treatment of the primary tooth that will eventually shed. Silver diamond fluoride can serve as an effective material in caries arresting and prevention. The ultimate interest in SDF centers around its favorable attributes, i.e., regulation of pain and infection, simplicity of usage, cost-effectiveness of the material, minimal requirement of training, less chair side time (one minute, once per year), and its noninvasive property.

The major drawback of SDF which contain silver compounds is the black staining effect on the carious tissue. This discoloration is caused due to oxidation of ionized silver into metallic silver; which possibly hinders the acceptance by patients or by their parents who value esthetics.<sup>[14]</sup> Usage in higher concentrations or repeated application of SDF leads to the formation of silver phosphate, which results into black staining of carious enamel and dentin, but not sound tooth tissue.<sup>[15]</sup> To combat the staining problem, potassium iodide can be applied to form a creamy white substance of silver iodide.<sup>[16]</sup> Tannic acid from boiled tea has also been suggested as an inexpensive substitute for stain removal.<sup>[17]</sup>

For decades, stainless steel crowns have been considered the most easily placed and the most durable of all restorations outperforming amalgam and direct composites.<sup>[18]</sup> But for the better esthetic looks the zirconia crown were placed in the maxillary anterior teeth. Zirconia crowns also known as “ceramic steel” as it provides tooth like esthetics and strength close to available metal crowns have been in use in dentistry for the last one decade. Zirconia is a crystalline dioxide of zirconium. The zirconia crowns not only look more translucent, but are almost five times stronger than the porcelain fused to the metal crowns as the zirconia crowns are

milled from a single densely sintered block of crystal. Zirconia crowns provide more strength in less volume, are thermostable with low heat conductivity, low thermal expansion and stable chemical resistance. Cyclical stresses are also well tolerated by this extremely biocompatible material.<sup>[19]</sup>

Thin labial structure of the prefabricated zirconia crowns resembles natural primary anterior tooth which provide better gingival tissue adaptation. No additional steps are required in facing placement unlike open faced stainless steel crowns, chair side time is decreased and additional step of laboratory fabrication is eliminated. The zirconia crowns manufactured for use in pediatric dentistry are available in different sizes which allow better fit and reduced chair side time.

Zirconia provides highly polished surface thus preventing staining and plaque accumulation and can be placed by simple technique. A moderate level of translucency makes it acceptable for esthetically demanding clinical cases, specially in anterior teeth. The zirconia crowns present superior durability as it is reported in the present case and there are no chances of facing loss as in pre-veneered stainless steel crowns. A good balance of strength, precision, and translucency allows zirconia-based restorations to conciliate a variety of clinical situations.<sup>[20]</sup>

## CONCLUSION

The treatment described in the case report is simple and effective and represents a promising alternative for rehabilitation of severely decayed or fractured primary anterior teeth and decayed maxillary and mandibular posterior teeth. The technique presented here can be added as a treatment option to restore primary incisors and arrest the progression of dental caries in posterior deciduous teeth for pediatric dentists due to their unparalleled advantages, including working time, esthetics and improved microstructure. However, costs should be thoroughly compared with other alternative

methods while choosing a material for the treatment.

## REFERENCES

1. Togoo RA: Early Childhood Caries-Cause, Diagnosis & Management. International Journal of Health Sciences and Research (IJHSR). 2012;1(2):148-60.
2. Kamalaksharappa SK, Dasgupta S. Effectiveness of Silver Diamine Fluoride in Children with Early Childhood Caries: A Systematic Review and Meta-analysis. World J Dent. 2018;9(4):327-32.
3. Çolak H, Dülgergil ÇT, Dalli M, Hamidi MM: Early childhood caries update: A review of causes, diagnoses, and treatments. J Nat Sci Biol Med. 2013;4(1):29-38.
4. Ashima G, Sarabjot KB, Gauba K, Mittal H: Zirconia crowns for rehabilitation of decayed primary incisors: an esthetic alternative. J Clin Paediat dent. 2014;39(1):18-22.
5. Rosenblatt A, Stamford TC, Niederman R. Silver diamine fluoride: a caries “silver-fluoride bullet”. J Dent Res 2009 Feb;88(2):119-125.
6. Bedi, R.; Infirri, JS. Oral health care in disadvantaged communities. London: FDI World Dental Press; 1999
7. Setty JV, Srinivasan I. Knowledge and awareness of primary teeth and their importance among parents in Bengaluru City, India. Int J Clini Pediatr dent. 2016; 9:56.
8. Yee R, Holmgren C, Mulder J, Lama D, Walker D, van Palenstein Helderma W. Efficacy of silver diamine fluoride for arresting caries treatment. J Dent Res. 2009; 88(7): 644-647
9. Aparecida-Valdeci de Souza MI, Cavaleiro JP, Giroto-Bussaneli D, Jeremias F, Cilense-Zuanon AC. Aesthetic rehabilitation with strip crowns in Pediatric Dentistry: a case report. CES Odontología. 2018; 31:66-75.
10. Douglass JM, Clark MB. Integrating oral health into overall health care to prevent early childhood caries: need, evidence, and solutions. Pediatr dent. 2015;37:266-74.
11. Croll T, Helpin M. Prefabricated resin veneered stainless steel crowns for restoration of primary incisors. Quintessenz Int. 1996;27:309-313.
12. Zou J, Meng M, Law CS, Rao Y, Zhou X. Common dental diseases in children and malocclusion. Int J oral sci. 2018;10:1-7.
13. Holan G, Needleman HL. Premature loss of primary anterior teeth due to trauma—potential short- and long- term sequelae. Dent Traumatol. 2014; 30:100-6.
14. Fung MH, Wong MC, Lo EC, Chu CH. Arresting early childhood caries with silver diamine fluoride—a literature review. Oral Hyg Health. 2013; 1:117.
15. Peng JJ, Botelho MG, Matinlinna JP. Silver compounds used in dentistry for caries management: a review. J Dent. 2012; 40(7): 531-541.
16. Chu CH, Lo EC. Promoting caries arrest in children with silver diamine fluoride: a review. Oral Health Prev Dent. 2008; 6(4): 315-321.
17. Yee R, Holmgren C, Mulder J, Lama D, Walker D, van Palenstein Helderma W. Efficacy of silver diamine fluoride for arresting caries treatment. J Dent Res 2009 Jul; 88(7): 644-647.
18. Castro AA: Evaluation of the Clinical Performance of Pedo Jacket Crowns in the Treatment of Maxillary Anterior Teeth with Early Childhood Caries: A Prospective Clinical and Laboratory Study. 2014.
19. Al-Amleh B, Lyons K, Swain M. Clinical trials in zirconia: a systematic review. J Oral Rehabil. 2010; 37(8):641-52.
20. Chang YY. Maximizing esthetic results on zirconia-based restorations. Gen Dent. 2011; 59(6):440-5.

How to cite this article: Tyagi T, Rao D, Panwar S et.al. Full mouth rehabilitation of paediatric patient with early childhood caries-a case report. *International Journal of Science & Healthcare Research*. 2021; 6(1): 95-100.

\*\*\*\*\*