

“Pyogenic Granuloma”- Is the Name Justified?: A Case Series

Sangita Show¹, Arka Kanti Dey²

¹Dental Surgeon (Ex- PGT, Dr. R.Ahmed Dental College & Hospital Kolkata), Consultant Periodontist, Durgapur, West Bengal.

²Dental Surgeon cum Clinical Tutor / Demonstrator, Diamond Harbour Medical College and Hospital, West Bengal.

Corresponding Author: Sangita Show

ABSTRACT

Pyogenic granuloma is a non-neoplastic, tumor like growth (inflammatory hyperplasia) affecting skin and oral mucosa. These lesions appear in the mouth due to physical trauma, hormonal factors etc. They attain various clinical and histological forms in the oral cavity. This article presents four case reports of pyogenic granuloma of the gingiva including their management, histopathological features and highlight why the term “pyogenic granuloma” is a misnomer.

Keywords: Pyogenic granuloma, gingiva, surgical growth excision.

INTRODUCTION

Pyogenic granuloma comprising about 1.85% of all oral pathoses, [1] possess an array of various nomenclatures like “granulation tissue-type hemangioma”, “granuloma gravidarum”, “lobular capillary hemangioma”, “pregnancy tumor”, “tumor of pregnancy” and “granuloma telangiectacticum” (due to evidence of vascularity seen in histological diagnosis). [2]

Pyogenic granuloma is a benign reactive lesion of vascular origin that represents an ebullient reaction by connective tissue to a certain stimulus or injury. Usually found in the oral cavity or on the skin, but seldom may occur in the gastrointestinal tract. It presents as tumor-like mucocutaneous overgrowth and a number of etiologic factors may contribute to its development like chronic low-grade

physical trauma, hormonal imbalance, microbial factors and certain drugs. [3]

Hullihen in 1844 described the first case of pyogenic granuloma. Subsequently in 1897, pyogenic granuloma was described as “botryomycosis hominis.” Hartzell in 1904 coined the term “pyogenic granuloma” or “granuloma pyogenicum. Angelopoulos termed it as “hemangiomas granuloma” on account of the presence of numerous blood vessels and the inflammatory nature of the lesion. [3] Similarly Cawson *et al.* [2] has described it as “granuloma telangiectacticum” due to the presence of numerous blood vessels seen in histological sections. Also two forms of pyogenic granulomas, the lobular capillary hemangioma (LCH) and the non-lobular capillary hemangioma (non-LCH) were described.

The term “pyogenic granuloma” is not justified since the tumour is neither associated with pus nor does it histologically resemble a granuloma. [5,6,7] Oral pyogenic granulomas show a higher predilection for gingiva, accounting for about 75% of the total cases. Although it may occur at any age, but is more commonly seen during the second and third decades of life. [4-7]

Pyogenic granuloma usually presents as an erythematous, painless growth, localized in the gingiva and grows quickly, bleeds easily on slight traumatization. [8] Tongue, lips, palate and

buccal mucosa are the other typical intra-oral sites of occurrence [9,10,11]

Histo-pathological investigation is required for its final definitive diagnosis, as it might be often confused with fibroma, parulis, peripheral giant cell granuloma, peripheral ossifying fibroma, hemangiopericytoma, leiomyoma, hemangioendothelioma, kaposi's sarcoma, pregnancy tumor, and post-extraction granuloma. Management of pyogenic granuloma includes surgical excision, thorough curettage of the adjacent teeth and root surfaces. This prevents recurrence due to incomplete surgical removal. [12-13]

This article encompasses a series of four different cases of pyogenic granuloma in both male and female patients along with histological findings and management. Also why the term pyogenic granuloma is a misnomer has been highlighted.

CASE PRESENTATION

Case 1:

A 42 year old female without comorbidities reported to the Department of Periodontics, complaining of a swelling in the upper front jaw region, which caused discomfort while eating, chewing as well as esthetically unpleasant. The patient reported that she noticed the swelling 7 years back, which was painless and gradually increased in size; however she never consulted a doctor. Intraoral examination revealed a firm pale pink, large sessile lobulated gingival overgrowth extending on facial surfaces of 11, 12 and 21 with a dimension of approximately 22 mm x 11mm x 4 mm.

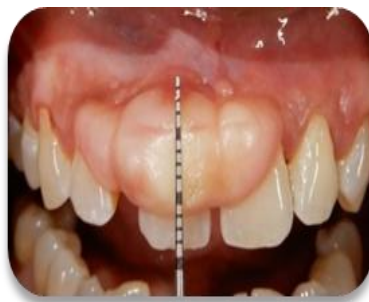
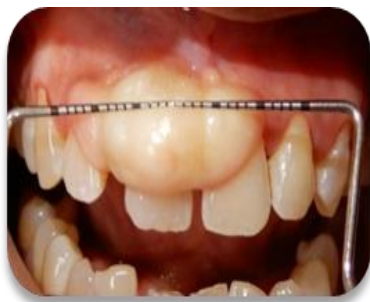

Fig 1 (a & b): Pale pink, firm, sessile growth in relation to teeth # 21, 11 & 12, of 23 mm x 11 mm x 4 mm dimension

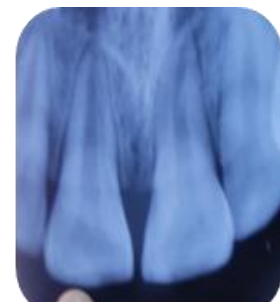
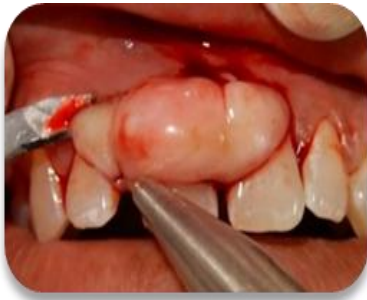
Fig 2: IOPAR of involved teeth

The lesion had a smooth surface devoid of any surface ulcerations and it appeared ovoid in shape [Figure 1 a& b]. Oral hygiene was not upto the mark and the mouth showed substantial amounts of calculus. No mobility was noted with the associated teeth. Radiographically, alveolar bone in the region of the growth appeared normal [Figure 2]. Routine blood profile was normal. Following oral prophylaxis the lesion was excised under aseptic conditions. Excision of the lesion up to and excluding the mucoperiosteum was carried out under local anesthesia using a scalpel and blade, followed by thorough curettage and scaling of the involved teeth. Interdental sutures were placed and primary hemostasis was achieved [Figure 3 & 4]. Periodontal dressing was placed and the patient was recalled after 1 week for removal of the pack and follow up [Figure 5]. The excised tissue specimen [Figure 6] was sent to the Department of Oral Pathology for histologic examination.

Histopathological report revealed parakeratinized stratified squamous epithelium, the underlying connective tissue stroma was composed of bundles of collagen fibers, fibroblast, fibrocytes, vascular spaces with endothelial cell proliferation. Diffuse chronic inflammatory cell infiltration was present [Figure 7]. Overall histological features were suggestive of pyogenic granuloma. Patient was recalled after 2 weeks [figure 8] and followed upto 6 months with no recurrence of the lesion.



3(a & b): Surgical growth excision with using a scalpel and blade

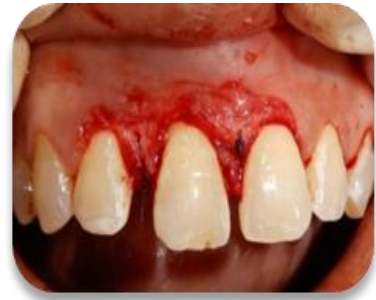
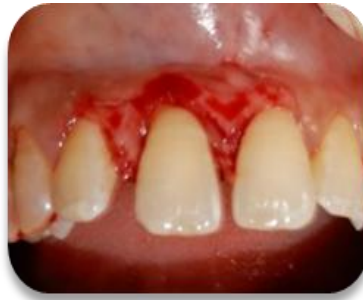
Fig 4: suture placed and primary hemostasis achieved

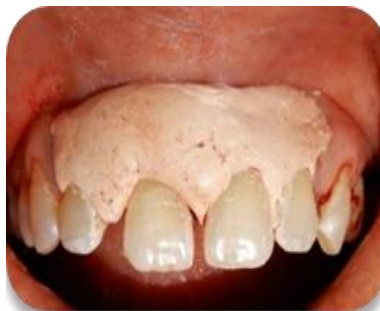

Fig 5: periodontal dressing given

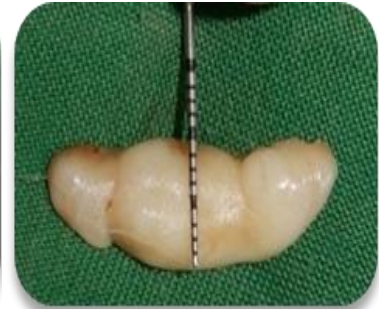
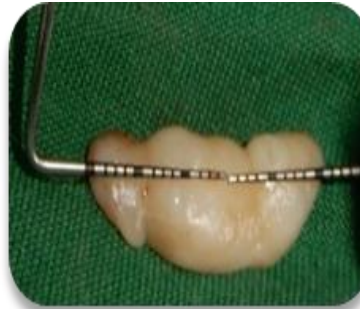
Fig 6: Excised tissue (30 x 9 mm) sent for histopathological assessment

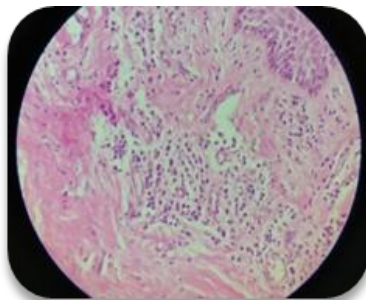


Fig 7: Histopathological slide

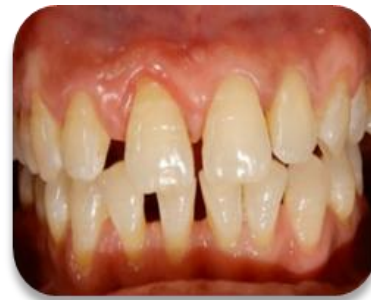

Fig 8: Post-operative follow up (2 weeks)

Case 2:

A 53 years old female patient without comorbidities was referred to the Department of Periodontics with the chief complain of a lesion on her hard palate. As per the patient's statement, initially the lesion was small (8 months back) when she noticed the lesion for the first time but later it grew in size to attain its present form. The patient was a denture wearer since past 6 years. Clinical examination revealed reddish pink, firm, pedunculated, exophytic lesion (15 mm x15 mm) dimensions painless and with a tendency for bleeding on slight provocation in relation to hard palate. The lesion depicted surface pseudomembrane along with certain areas of erythema [figure

9 a & b]. Routine blood profile was conducted and the lesion was excised under aseptic conditions, under local anesthesia using a scalpel and blade. Palatal sutures were placed and primary hemostasis was achieved [Figure 10]. The patient was recalled after 1 week for follow up [Figure 12]. The excised tissue specimen [Figure 11] was sent to the Department of Oral Pathology for histological examination.

Histopathological analysis depicted parakeratinized stratified squamous epithelium backed by hypervascular connective tissue stroma. Multiple blood vessels of varying sizes were noted. In few areas pleomorphic cells were present. Diffuse chronic inflammatory cell infiltrate

was present. Hence overall features [Figure 13]. indicated a case of pyogenic granuloma

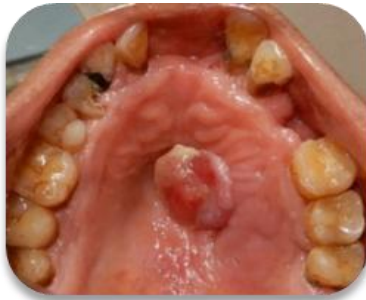

Fig 9 (a & b). Reddish pink, firm, pedunculated growth in relation to hard palate of 15 mm x 15 mm dimension

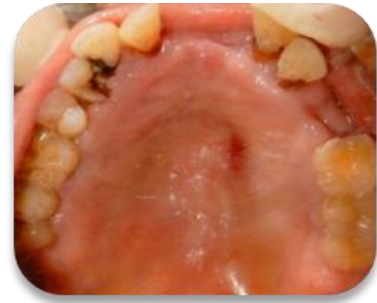
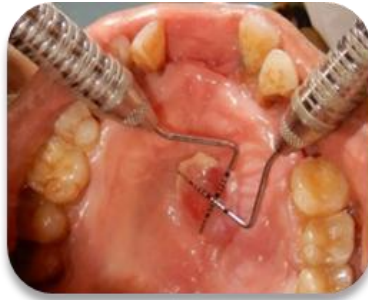
Fig10 : Biopsy site after growth excision

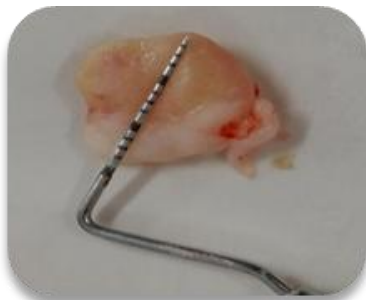

Fig11: Excised tissue sent for histopathological assessment

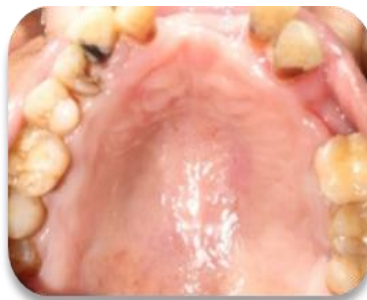

Fig 12: Post-operative follow-up (1week)

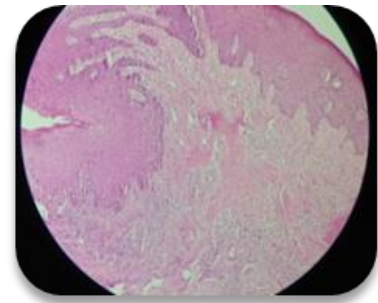


Fig13: Histopathological slide

Case 3:

A 37 years old male patient without any systemic diseases reported to the Department of Periodontics with the complain of discomfort during eating food dates back 3 months ago, the lesion had increased its size. Clinical evaluation revealed 14mm x15mm mm large, reddish pink, soft, pedunculated, painless formation localized on the lingual mucosa in relation to interdental papilla region of 36,37 [Figure 14]. Periodontal evaluation revealed abundant deposits of plaque and calculus. After conducting routine blood profile the lesion was surgically excised using a scalpel and blade [Figure 15]. Primary hemostasis

was achieved and periodontal dressing was placed [Figure 16,17]. The patient was recalled after 1 week for follow-up [Figure 19]. The excised tissue specimen [Figure 18] was sent to the Department of Oral Pathology for histologic examination.

Histopathological findings reveal the presence of connective tissue stroma covered by an ulcerated stratified squamous epithelium. The connective tissue stroma is hypercellular showing multiple blood vessels with extravasated RBCs and endothelial cells. Dense chronic inflammatory cell infiltrate is evident. The overall features suggested a case of healed pyogenic granuloma.

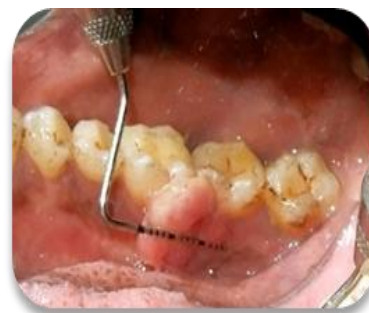
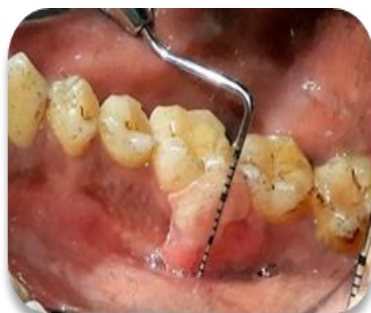
Fig 14 (a & b): reddish pink, soft, pedunculated growth in relation to lingual mucosa # 36, 37 of 14 mm x 15 mm dimension (reflector image)

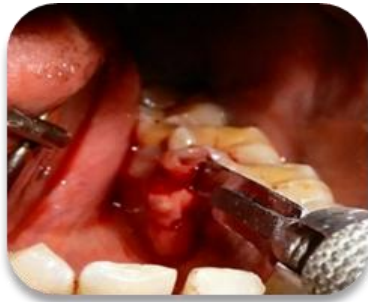

Fig 15: Surgical growth excision with scalpel and blade

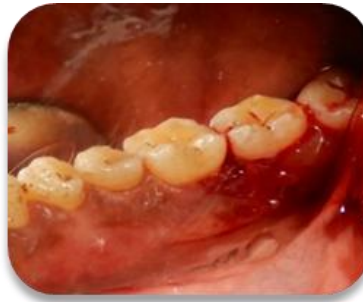

Fig 16: Site after surgical growth excision (reflector image)

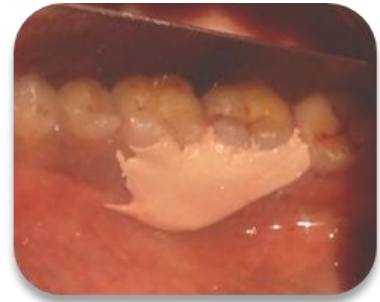

Fig 17: periodontal dressing given

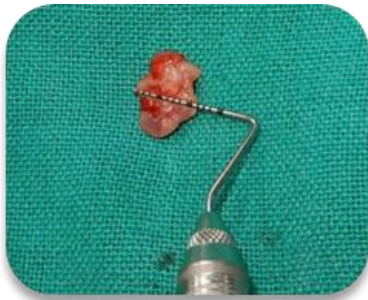

Fig 18: Excised tissue (11mm x14 mm) sent for histopathological assessment

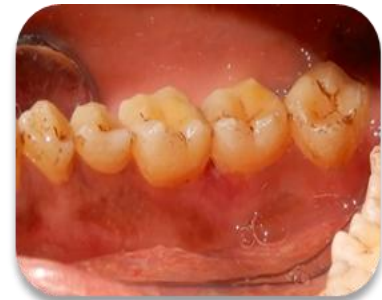
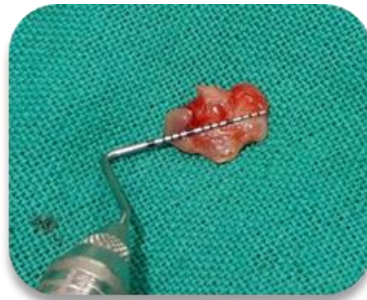
Fig 19: Post-operative follow-up (1week)

Case 4:

A 15 years old female patient without any systemic diseases was referred to the Department of Periodontics with the complain of a lesion in her upper front teeth region which dates back to 4 months ago, the lesion had increased its size. Clinical evaluation revealed (6mm x 6 mm) pale pink, small, soft, pedunculated, painless lesion with surface ulcerations, localized to the interdental papilla region of 11,21 [Figure 20]. Periodontal evaluation revealed abundant deposits of plaque and calculus. After conducting routine blood profile the lesion was excised under aseptic conditions, under local anesthesia using a scalpel and

blade [Figure 21]. Interdental sutures were placed and primary hemostasis was achieved [Figure 22]. The patient was recalled after 1 week for follow up [Figure 24]. The excised tissue specimen [Figure 23] was sent to the Department of Oral Pathology for histologic examination.

Histopathological findings reveal the presence of hyperplastic stratified squamous epithelium backed by connective tissue stroma. Multiple blood vessels are present and there is patchy chronic inflammatory cell infiltrate in the connective tissue stroma. The overall features suggestive of pyogenic granuloma.

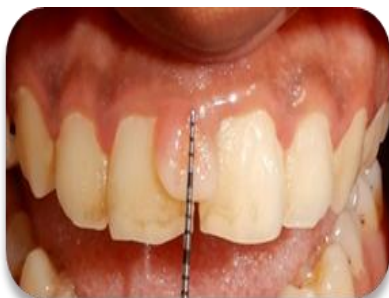

Fig 20 (a & b): pale pink, soft, pedunculated growth in relation to interdental papilla region of 11,21 of 6 mm x 6 mm dimension

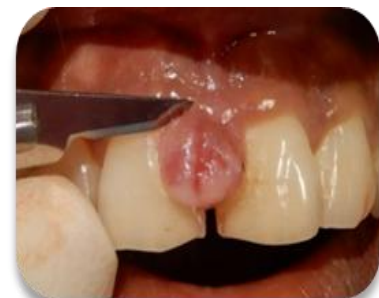
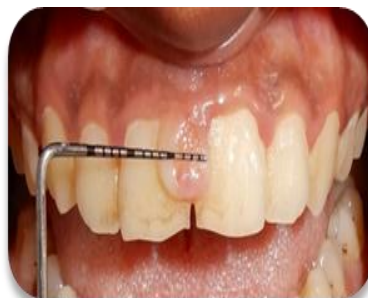
fig 21: surgical growth excision

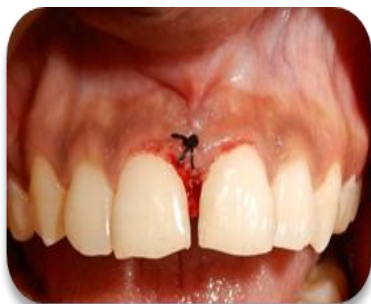

Fig 22: simple interrupted suture placed

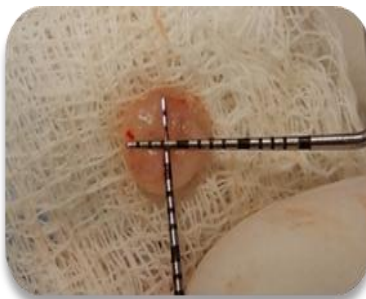


Fig23: Excised tissue (7 mm x 6 mm) sent for histopathological assessment

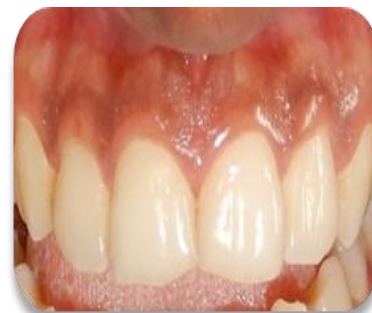

Fig 24: Post-operative follow-up (1week)

DISCUSSION

Pyogenic granuloma, as far as literature suggests, most of the cases result from mild trauma or inflammation leading to connective tissue overgrowth. [4] Other predisposing factors are viral oncogenes, hormones, microscopic arterial malformations, gene depression in the fibroblasts. [14,15] A large number of cases of intraoral pyogenic granulomas (more than 5%) are observed in pregnancy, thereby supporting the terms "pregnancy tumor" and granuloma gravidarum. [16] In all the four cases discussed, etiology includes abundant local deposits, which occurs due to a vicious cycle of inflammation, pain during brushing of teeth, which in turn impairs the oral hygiene thereby further aiding in the development of such lesions and are clinically presented as single nodule or pedunculated papula with smooth or lobular surface, sometimes ulcerated, of varying sizes. Matured lesions have a pink colour due to poor vascularization, and increased amount of collagen. [17] The predilection is higher in females in their second decade for occurrence of oral pyogenic granulomas although it can occur at all age groups, which may be attributed to the increased levels of circulating hormones like estrogen and progesterone. [7]

Two histological types of pyogenic granuloma has so far been reported in literature namely: lobular capillary hemangioma and non-lobular capillary hemangioma. [18] The first type clinically presents as sessile lesion and accounts 66.4% of the cases and the second type presents pedunculated lesion accounts to

77% of the cases. [4] It is worth mentioning that the term "pyogenic granuloma" is a misnomer since the lesions are not associated with production of pus and there are no clinical or histological evidence of true granulation tissue. [17] Intraoral gingival forms are usually located in maxilla. [17]

This article depicts four different cases of pyogenic granuloma, the probable etiologic factors applicable in these case included the presence of large amounts of calculus due to poor oral hygiene habits, repeated trauma while brushing as well as chewing due to the position of the lesion which is in accordance with Ainamo, [18] who pointed out the release of various endogenous and angiogenic growth factors contributing to the increased vascularity of the lesion with repeated trauma.

Out of the numerous treatment protocols, surgical excision is still the most widely used treatment method of choice, followed by deep curettage of the lesion, combined with removal of the periosteum and granulation tissue around the adjacent teeth. [17] Recurrence is noted in 15.8% of the cases. [1] Cryotherapy, laser excision etc are often utilized as alternative treatment approaches to prevent recurrence. [17] Various other treatment modalities include Nd: YAG laser, carbon dioxide laser, flash lamp, pulse dye laser, cryosurgery, electrodesiccation, sodium tetradecyl sulfate, sclerotherapy. [19] Our cases were followed up for a period of 1 year with subsequent intervals and no recurrences were noted.

CONCLUSION

Pyogenic granuloma is a common lesion affecting the skin and oral cavity, especially the gingiva. The article not only highlights the various etiologies, clinical features, histological presentations, treatment modalities, diagnosis, treatment and recurrence rates but also highlights that though the term pyogenic granuloma is frequently used but it is not associated with pus and histologically it resembles angiomatous lesion rather than granulomatous lesion indicating that the term "pyogenic granuloma" is a misnomer. The case series summarize four different cases of pyogenic granuloma which were treated and also followed up for a period of one year to ensure that there was no recurrence of the lesions.

REFERENCES

1. Bhaskar SN, Jacoway JR. Pyogenic granuloma- Clinical features, incidence, histology, and result of treatment: Report of 242 cases. *J Oral Surg* 1966; 24:391-8.
2. Cawson RA., et al. "Lucas Pathology of Tumors of Oral Tissues". 5th edition. Missouri: Mosby (1998): 252-254.
3. Sheiba R. Gomes, Quaid Johar Shakir, Prarthana V. Thaker, Jamshed K. Tavadia ; Pyogenic granuloma of the gingiva: A misnomer?- A case report and review of literature *Journal of Indian Society of Periodontology*-Vol 17, Issue 4, 2013
4. Gomes Sr, Shakir Q. J. Thaker P. V., Tavadia J. K. Pyogenic granuloma of the gingiva: amonomer? a case report and review of literature. *Journal of Indian Society of Periodontology*, 2013; 17:514-19.
5. Aghbali A.A., Hosseini S.V., Harasi B., Janani M., Mahmoudi S.M. Reactive Hyperplasia of the Oral Cavity: A Survey of 197 Cases in Tabriz, Northwest Iran. *J Dent Res Dent Clin Dent Prospect* 2010; 4:87-89.
6. Al-Rawi N. Localized Reactive Hyperplastic Lesions of the gingiva: clinicopathological study of 636 lesions from Iraq. *The Internet Journal of Dental Science* 2009; 7: 213-18.
7. Marla V, Shrestha A, Goel K, Shrestha S. The Histopathological spectrum of pyogenic granuloma: A Case Series. *Case Rep Dent*. 2016; 2016:ID1323798, 6p.
8. Kurian DB, Sasirekha D, Ebenezer D. Pyogenic Granuloma- a Case Report and Review. *IJDSR*. 2014 2(3), 66-68.
9. Akyol MU, Yalciner EG, Dolan AI. Pyogenic granuloma of the tongue. *Int J Pediatr Otorhinolaryngol*. 2001 May 11; 58(3):239-41.
10. De Giorgi V, Sestini S, Nardini P, Carli P. A 42years old man with a rapidly growing lesion of the soft palate. *CMAJ*. 2005 Aug 16; 173(4):367.
11. Patil K, Mahima VG, Lahari K. Extragingival pyogenic granuloma. *Indian J Dent Res*. 2006 Oct- Dec; 17(4):199-202.
12. Shafer WG., et al. "A Textbook of Oral Pathology". Philadelphia: W.B. Sanders Company (1983): 359-361.
13. Angelopoulos AP. "Pyogenic granuloma of the oral cavity statistical analysis of its clinical features". *Journal of Oral Surgery* 29.12 (1971): 840-847.
14. Davies MG, Barton SP, Atai F, Marks R. The abnormal dermis in pyogenic granuloma. Histochemical and ultrastructural observations. *J Am Acad Dermatol*. 1980 Feb; 2(2):132-42.
15. Vilamnn A, Vilamnn P, Vilamnn H. Pyogenic granuloma: evaluation of oral conditions. *Br J Oral Maxillofac Surg*. 1986 Oct; 24(5):376-82.
16. Kurian DB, Sasirekha D, Ebenezer D. Pyogenic Granuloma- a Case Report and Review. *IJDSR*. 2014 2(3), 66-68.
17. Bugshan A, Patel H, Garber K, Meiller TF. Alternative therapeutic approach in the treatment of oral pyogenic granuloma. *Case Rep Oncol*. 2015 Nov 14; 8(3):493-7.
18. Ainamo J. "The effect of habitual tooth cleansing on the occurrence of periodontal disease and dental caries". *Suom Hammaslaak Toim* 67.1 (1971): 63-70.
19. Jafarzadeh H., et al. "Oral pyogenic granuloma: A review". *Journal of Oral Science* 48.4 (2006): 167-175.

How to cite this article: Show S, Dey AK. "Pyogenic granuloma" - is the name justified?: a case series. *International Journal of Science & Healthcare Research*. 2020; 5(3): 390-396.
