

## Ceftriaxone Induced Rash Dermatitis: A Case Report

Vageeshwari Devuni

CMR College Of Pharmacy, Kandlakoya, Medchal road, Hyderabad.

### ABSTRACT

Cephalosporins and penicillins are the most widely used antibiotics for the treatment of common infections. Each one has a 4-membered dihydrothiazine beta-lactam ring, but 5-membered dihydrothiazine ring of penicillins is replaced by the 6-membered dihydrothiazine ring in the cephalosporins nucleus. Ceftriaxone, a cephalosporin is used for variety of infections. This drug is known to be associated with rare and mild side-effects such as Urticaria, skin rash, diarrhea, vomiting, transient neutropenia, and hemolysis. Drug hypersensitivity reactions are immunologic responses to medications. Causal relationship between the drug and the reaction is assessed depending on the lag period between the start of the drug and the appearance of the reaction, Antibiotic-related cutaneous drug reactions represent a common cause of dermatological consultations among hospitalised patients, and it is difficult to get the major culprit antibiotic because of the concomitant use of multiple systemic antibiotics. Management of Hypersensitivity reactions: Mild-moderate hypersensitivity reactions are managed by antihistamines and corticosteroids.

**Keywords:** Ceftriaxone, Rash, Dermatitis, Cephalosporin, Penicillin

### INTRODUCTION

Depending on their chemical structure, beta-lactam (BL) antibiotics are classified into 2 major classes, penicillins and cephalosporins, and 4 minor classes, monobactams, carbapenems, oxacephems and clavams. Cephalosporins and penicillins are the most widely used antibiotics for the treatment of common infections. Each one has a 4-membered beta-lactam ring, but the 5-membered dihydrothiazine ring of penicillins is replaced by the 6-membered

dihydrothiazine ring in the cephalosporins nucleus.

Monobactams contain a monocyclic ring structure, whereas carbapenems have a bicyclic nucleus comprised of beta-lactam ring with an association 5-membered ring. (1) Ceftriaxone, a cephalosporin is used for variety of infections. This drug is known to be associated with rare and mild side-effects such as Urticaria, skin rash, diarrhea, vomiting, transient neutropenia, and hemolysis. (2) Drug hypersensitivity reactions are immunologic responses to medications. The World Allergy organization recommends categorizing hypersensitivity reactions on the basis of timing of the appearance of symptoms as immediate (ie, develops within 1 hour of drug exposure) or delayed-type (i.e., onset after 1 hour of drug exposure) reactions (immunoglobulin E (Ig E)- mediated) hypersensitivity reactions pose the greatest clinical concern because of the risk of life-threatening anaphylaxis; delayed-type reactions most commonly present as rashes or skin lesions. (3) Antibiotic-related cutaneous drug reactions represent a common cause of dermatological consultations among hospitalised patients, and it is difficult to verify the major culprit antibiotic because of the concomitant use of multiple systemic antibiotics. Antibiotic allergy may present as immediate or delayed hypersensitivity reactions. Immediate reactions are usually immunoglobulin E (Ig E) mediated, whereas SCARs are T-cell mediated delayed hypersensitivity reactions. (4) Causal relationship between the drug and the reaction assessed depending on the lag period between the start of drug and the appearance of the reaction, responses to de-

challenge and de-challenge tests and the data available regarding the drug. <sup>(5)</sup> risk factors associated with development of such symptoms could be: patient related factors such as : Age(Young/ middle/ aged are more prone >>infants/ elderly), Gender (Women>>Men), Genetic polymorphisms, viral infections (human immunodeficiency virus, herpes infections) and previous reactions to drugs/ diseases such as presence of asthma, chronic obstructive pulmonary disease, pregnancy, cardiovascular diseases, allergic rhinitis, eczema and mastocytosis. Drug related factors such as: High molecular weight compounds and hapten forming drugs are more immunogenic, Route of administration (topic>intravenous/ intramuscular>oral) and dose of drug administration (frequent exposure to drugs/prolonged>single dose. Drugs that interfere with Drug sensitivity testing: Certain drugs can suppress an antibiotic susceptibility testing. They are: H1-antihistamines, imipramine, phenothiazines, dopamine, clinicians, monteleukast and corticosteroids. Also presence of certain diseases like: eczema, urticaria and infectious diseases like leprosy can result in a false positive test. Management of Hypersensitivity reactions: Mild-moderate hypersensitivity reactions are managed by antihistamines and corticosteroids. Severe hypersensitivity reactions like anaphylactic shock are usually managed by oxygen therapy, intravenous fluids, vasopressors such as corticosteroids, adrenaline and chlorpheniramine. <sup>(6)</sup>

### CASE REPORT

A 28 years old male patient came with complaints Rash and red coloured raised skin lesions over face, trunk, and upper limbs since 5 days. Had history of intense itching associated with lesions. On Cutaneous examination found diffuse erythematous, blanchable, MP rash over cheeks and abdomen. Multiple, erythematous, papules are + over neck, back, scalp. His vitals were found to be stable. Laboratory findings: Liver function :

Total serum Bilirubin-1mg%, Direct bilirubin-0.3mg% units, SGPT-144IU/L,RBS- 17mg%, blood urea-29mg%, serum creatinine-0.6mg%, ALP-233 IU/L, serum electrolytes: Na-136, K-3.8, Cl- 108, Hb-11.1gm%, Rbc-4.3mill/mm<sup>3</sup>,Wbc-8,500/mm<sup>3</sup>,Plt-8,500/mm<sup>3</sup>,sr.Creatinine-1mg%.

Past medication history: Tab.Monocef 1gm BD, Inj. Depo-Medrol 80 mg.

Based on Subjective and Objective details it is confirmed as Ceftriaxone induced Skin rash. The patient was initially treated with Inj. Decadent 1CC IV BD, Inj. Pan 40mg IV bbf, Inj. Avil 1CC IV BD, T. B.Complex, Calcium and Vit. C OD, liquid paraffin for external application.

He was discharged with T. Wysolone 30 mg for 2 weeks, T.Pan 40 mg OD, T.Cpm OD, T. Paracetamol TID, and topical applications like liquid paraffin, soframycin ointment were prescribed.

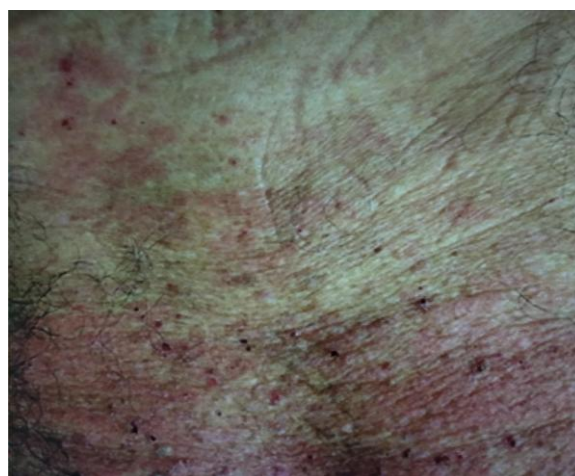


Figure 1: Clinical Image

### DISCUSSION

Ceftriaxone, a third-generation cephalosporin, is being commonly prescribed since 1984. (It is used as an antibiotic across almost all specialties for various conditions. Ceftriaxone-induced urticaria, rash, exanthema, and pruritus are the most common adverse effects. <sup>(7)</sup> One of the major problems for the allergologic evaluation of adverse reactions to cephalosporins is that many of the latter are not available in aqueous solution for therapeutic use, and therefore they require

manipulation for both in vivo or in vitro testing. <sup>(8)</sup> When a patient exposed to certain drug like cephalosporin production of IgE antibodies fix to mast cells then again re-exposure to the same antigen antibody reaction occurs on the mast cells surface then release of inflammatory mediators like histamines, 5HT, PGs, LTs, PAF causes skin rashes. Adverse effects were infrequent, and in only one instance was it necessary to discontinue treatment. <sup>(8)</sup> Additional therapy for drug hypersensitivity reactions are largely supportive and may include topical corticosteroids, oral antihistamines and, in severe cases, systemic corticosteroids. <sup>(9)</sup> Reactions limit themselves in a period of less than fifteen days. Though internal organs are not usually involved, there can be a life-threatening condition as a result of secondary infections. <sup>(10)</sup>

## CONCLUSIONS

Ceftriaxone is a commonly used antibiotic in both inpatient outpatient department but have multiple potential adverse events. Clinicians should be aware of the possibility of anaphylaxis occurring with the test dose of Ceftriaxone, especially because such a reaction could go unnoticed in patients with life-threatening infections and unstable vital signs. Hence, it is important to recognize it rapidly and treat it effectively.

## REFERENCES

1. E.Dias de Castro, A. Leblanc, A. Sarmento, et al. An unusual case of delayed-type hypersensitivity to Ceftriaxone and meropenem. J.R. Cernadas1 Vol 47, N 6, 225-227, 2015, Allergy and immunology Division, Hospital S. Joao, E.P.E., Porto, Portugal

2. Vivek S. Guleria, Mukesh Dillon, and Barrel Nathaniel. Ceftriaxone induced drug rash with eosinophilia and systemic symptoms. J Res Pharm Pract. 2014 Apr-Jun; 3(2): 72-74.
3. Davey P.Legendre Christina A. MuznyGailen D, et al. Antibiotic Hypersensitivity Reactions and Approaches to Desensitization. Clinical Infectious Diseases, volume 58, Issue 8, 15 April 2014, Pages 1140-1148.
4. Ying- Fang Lin, Chih-Hsun Yang, Hu sindy, et al. Severe Cutaneous Adverse Reactions Related to Systemic Antibiotics. Clinical Infectious Diseases, Volume 58, Issue 10, 15 May 2014, pages 1377-1385.
5. Infernal kaur and Joinder Singh. Cutaneous drug reaction with intravenous Ceftriaxone. Indian J Pharmacol. 2009 ANTONINO 285.
6. Sereen Rose Thomson,Balaji Ommurugan, et al. Ceftriaxone-induced Hypersensitivity reactions following Intradermal Skin test: Case series. 2017; Oct; 11(10):FR01-FR04.
7. Antonino Romano MD, Cristobalina Mayorga PhD, et al. Immediate allergic reactions to Cephalosporins: Cross-Reactivity and Selective responses.doi.org/10.1067/mai.2000.111147.
8. BE Sculpt, HC Neu. Ceftriaxone in the treatment of serious infections, particularly after surgery. American Journal of Surgery 148(4A), 35-40, 1984.
9. Richard Warrington, Fanny Silviu-Dan. Drug allergy. Allergy Asthma Clin Immunological.2011;7(suppl.1):S10.
10. Hikmet Lekin Nacaroglu, Mehmet Celegen, et al. Acute generalized exanthematous pustulosis induced by Ceftriaxone use. Posted Dermatol Allergol. 2014 Aug; 31(4): 269-271.

How to cite this article: Devuni V. Ceftriaxone induced rash dermatitis: a case report. International Journal of Science & Healthcare Research. 2019; 4(2): 176-178.

\*\*\*\*\*