

Skeletal Effect of Lamotrigine Administration in Pregnant Albino Rats

Muna Anwer Mohammed Kutb¹, Huda Adulwadood Mohammed Omer²

¹Department of Morphology, Histopathology Unit, Faculty of Medicine, Aden University, Yemen,
Aden- AL- Maalla. Yemen.

²Department of Paraclinic, Forensic Medicine & Toxicology Unit, Faculty of Medicine, Aden University,
Yemen, Aden- AL-Mansorrhah. Yemen

Corresponding Author: Muna Anwer Mohammed Kutb

ABSTRACT

Background: Lamotrigine is a broad-spectrum agent that was approved for use in 1994 as an adjunctive treatment in adults with partial-onset seizures, later approval was granted for use in adults and children aged 2 years and older with generalized seizures associated with Lennox - Gastaut syndrome (childhood epileptic encephalopathy) and for conversion to monotherapy.

Methods: Sixty adult non pregnant female albino rats and 30 male rats of the same strain weighted (150-200 grams) purchased from animal house of faculty of medicine, Assiut University. Animals were classified randomly into three groups; each group contained 20 pregnant female rats. Control groups (I), B-Treated groups: Ia: received therapeutic dose of lamotrigine (5.4 mg/day) and Ib: received $\frac{1}{4}$ LD₅₀ of lamotrigine (32 mg/kg). The fetuses in this subgroup were treated according to modified Dawson's technique for staining fetal skeleton. The skeletal system examination included: I) Bones of axial skeleton and II) Bones of the appendicular skeleton.

Result: There is a very highly statistical significant reduction in the mean of complete craniofacial ossification centers of treated groups in comparison with the control group. Also reduction in the mean of complete vertebral, thoracic, lumbar, sacral, caudal, metacarpal and metatarsal ossification centers of Ib group.

Conclusion: Lamotrigine in therapeutic dose is the drug of choice to be used by epileptic pregnant women.

Key words: Lamotrigine, skeletal examination, therapeutic dose, albino rat, $\frac{1}{4}$ LD₅₀, ossification centers.

INTRODUCTION

Epilepsy is the most common serious chronic neurological condition, which affecting more than 3 million people in the United State. [1] Most of those affected, including women of childbearing age, will require long term treatment with antiepileptic drugs to prevent seizures. [2-4] The condition is characterized by repeated seizures caused by the excessive electrical firing of a number of neurons. [5]

The treatment of women of childbearing age who have epilepsy raises questions because of the interactions between epilepsy, antiepileptic therapy and different aspects of reproductive life. [6]

Although the majority of children born to women with epilepsy are normal, they are at increased risk for malformations as well as for poor neuropsychological outcomes. [7]

The use of antiepileptic drugs in women with epilepsy of child-bearing potential is a delicate balance between seizure control and adverse effects of AEDs, which are both potentially harmful to the developing fetus, [8,9] neurological development, growth and subsequent pediatric progress which presents unique challenges to both the clinicians and their patients. [10,11]

Control of maternal epilepsy including drug selection and dose adjustment, must be balanced with the fetal and neonatal risks associated with AEDs, as well as the clinical status of the patient. [10]

The incidence of congenital malformations among infants of mothers with epilepsy treated with AEDs during pregnancy (especially in the first trimester of the pregnancy when the organogenesis occurs) is higher than those among infants of normal controls and among infants of mothers with epilepsy whose mothers were not treated. [6,12]

Numerous studies have attempted to assess the teratogenic effects of antiepileptic drugs (AEDs) since the first observations of an association between use of anticonvulsants and an increased risk of birth defects were published 40 years ago. [13] These potential teratogenic effects are a major concern for all women with epilepsy that are of childbearing potential. Unlike many other medications, antiepileptic drug treatment generally cannot be withdrawn even when pregnancy is planned, since uncontrolled seizures may be harmful to the mother as well as the fetus. The risks associated with uncontrolled seizures thus have to be balanced against the teratogenic risk. [13]

Lamotrigine is a broad-spectrum agent that was approved for use in 1994 as an adjunctive treatment in adults with partial-onset seizures, later approval was granted for use in adults and children aged 2 years and older with generalized seizures associated with Lennox - Gastaut syndrome (childhood epileptic encephalopathy) (LGS) and for conversion to monotherapy. [14,15] Lamotrigine (LTG) is a triazine compound that is chemically unrelated to any of the other AEDs. It was developed as an antifolate agent based on a theory that the mechanism of some AEDs is related to their antifolate property. [16]

This novel antiepileptic drug shares a very similar mechanism of action with conventional antiepileptic drugs; carbamazepine and phenytoin. The drug binds to the inactivated form of voltage-dependent sodium channels. [17] thus limiting the sustained repetitive firing of neurons without any substantial effect upon normal synaptic activity, lamotrigine also

seems to act through the GABAergic mechanism reduces calcium currents via voltage sensitive calcium channels and reduction of glutamate release. [18] It has a weak antifolate effect that is unrelated to its antiseizure efficacy. It is hence used both in epilepsy and in bipolar disorder. [19] This effect may be encountered only at supratherapeutic concentrations. [18]

Aim of the work

The aim of this study is to evaluate the effects of the therapeutic doses and $\frac{1}{4}$ LD₅₀ of lamotrigine on the skeletal structure of albino rat fetuses.

MATERIALS AND METHODS

This study is a randomized single blind control trial in which the skeletal structure of albino rat fetuses of lamotrigine (AEDs) was studied. Lamotrigine was used in two doses (Therapeutic and $\frac{1}{4}$ LD₅₀).

A) Animals

Sixty adult non pregnant female albino rats and 30 male rats of the same strain weighted (150-200 grams) purchased from animal house of faculty of medicine, Assiut University, the female rats were separated and housed for one week to be sure that they were non pregnant.

All over the period of experiment, the animals were housed in capacious cages with natural ventilation at room temperature (37°C). They received tap water and food (rodent pellets) ad libitum.

Adult two female albino rats were mated with one male rat of the same strain in the evening, a successful mating was known by vaginal redness and slight swelling on the following morning and regarded as Day 0 of gestation (GD0) [20,21] The males were returned to their separate cages. .

Animals were classified randomly into three groups; each group contained 20 pregnant female rats. .

A-Control groups::

Group I: control group (n=20), received normal saline. .

B-Treated groups::

Group IIa: received therapeutic dose of LTG (n=20).

Group IIb: received ¼ LD₅₀ of LTG (n=20). Animals in IIa group were given the therapeutic dose = 5.4 mg/day of lamotrigine, [22] dissolved in 0.5 ml normal saline (0.25 ml twice/day). While animals in IIb group were given ¼ LD₅₀ = 32 mg/kg [23] of lamotrigine dissolved in 3.2 ml normal saline (1.6 ml twice/day).

Lamotrigine.

The fetuses in this subgroup were treated according to modified Dawson's technique for staining fetal skeleton. [24]

1-The fetuses were eviscerated through a small midline abdominal incision and fixed in 95% alcohol. The incision permits the free access of reagent.

2-The specimens were rinsed in 1% potassium carbonate for 4 weeks.

3-The soft parts are cleared by immersing the specimens in 1% potassium hydroxide for ten days, until the bones were clearly visible through the soft tissue.

4-Staining was done by immersing the specimen in freshly prepared 0.1% aqueous

solution of alizarin red S to which 6-10 drops of 1% potassium hydroxide (KOH) was added.

5-The specimens were depolarized by immersion in an aqueous solution of 20% glycerine and 1% KOH until the soft tissues became entirely transparent showing the ossified skeleton stained deeply red.

6-When bones were clearly visible, the specimens were transferred through several concentrations of 50, 70, 80 and 90% solution of glycerine in water, and lastly was preserved in 100% glycerine to which few drops of formaldehyde solution were added to prevent fungal growth. Skeletal system was then examined.

The skeletal system examination included:

Bones of axial skeleton: (Skull "craniofacial bones", Vertebral column "thoracic, lumber, sacral and caudal vertebrae", Sternum and Ribs). [25]

Statistics:

The Statistical Package for Social Sciences (SPSS) version 20 was used in data analysis.

RESULTS

Table (1): Effect of maternal lamotrigine administration on craniofacial ossification centers (13 bones) of albino rat fetuses.

Groups	No. of Fetuses	Total No. of centers	Mean ±SD of complete centers	No of complete centers		No of incomplete centers		No of absent centers	
				No	%	No	%	No	%
G I (control)	68	884	13.00 ±0.0	884	100	0	0	0	0.0
G IIa	47	611	12.33 ± 0.8***	580	94.9	31	5.1	0	0.0
G IIb	37	481	9.00 ± 1.2***	333	69.2	68	14.1	80	16.7

Results are shown as mean±SD. No: Number
 - Comparison between control versus each treated group, *** p<0.001 is very highly significance. %: The percentage calculated from number of incomplete centers / total number of centers X 100.

Table (2): Effect of maternal lamotrigine administration on vertebral ossification centers (25 bones) of albino rat fetuses.

Groups	No. of Fetuses	Total No of centers	Mean ±SD of complete centers	No of complete centers		No of incomplete centers		No of absent centers	
				No	%	No	%	No	%
GI(control)	68	1700	25.00 ± 0.0	1700	100.0	0	0.0	0	0.0
G IIa	47	1175	25.00 ± 0.0	1175	100.0	0	0.0	0	0.0
G IIb	37	925	20.83 ± 1.7***	771	83.4	0	0.0	154	16.6

Table (3): Effect of maternal lamotrigine administration on thoracic ossification centers of albino rat fetuses (T1-12):

Groups	No. of Fetuses	Total No of centers	Mean ±SD of complete centers	No of complete centers		No of incomplete centers		No of absent centers	
				No	%	No	%	No	%
GI(control)	68	816	12.00 ± 0.0	816	100.0	0	0.0	0	0.0
G IIa	47	564	12.00 ± 0.0	564	100.0	0	0.0	0	0.0
G IIb	37	444	10.00 ± 1.4***	370	83.3	0	0.0	74	16.7

Table (4): Effect of maternal lamotrigine administration on lumbar ossification centers of albino rat fetuses (L1-6)

Groups	No. of Fetuses	Total No of centers	Mean±SD of complete centers	No of complete centers		No of incomplete centers		No of absent centers	
				No	%	No	%	No	%
G I (control)	68	408	6.00 ± 0.0	408	100.0	0	0.0	0	0.0
G IIa	47	282	6.00 ± 0.0	282	100.0	0	0.0	0	0.0
G IIb	37	222	5.00±0.9***	185	83.3	0	0.0	37	16.7

Table (5): Effect of maternal lamotrigine administration on sacral ossification centers of albino rat fetuses (S1-4):

Groups	No. of Fetuses	Total No of centers	Mean ±SD of complete centers	No of complete centers		No of incomplete centers		No of absent centers	
				No	%	No	%	No	%
G I (control)	68	272	4.00±0.0	272	100.0	0	0.0	0	0.0
G IIa	47	188	4.00 ± 0.0	188	100.0	0	0.0	0	0.0
G IIb	37	148	3.33± 0.8***	123	83.1	0	0.0	25	16.9

Table (6): Effect of maternal lamotrigine administration on caudal ossification centers of albino rat fetuses (C1-3):

Groups	No. of Fetuses	Total No of centers	Mean ±SD of complete centers	No of complete centers		No of incomplete centers		No of absent centers	
				No	%	No	%	No	%
G I (control)	68	204	3.00 ± 0.0	204	100.0	0	0.0	0	0.0
G IIa	47	141	3.00 ± 0.0	141	100.0	0	0.0	0	0.0
G IIb	37	111	2.50 ±0.5***	93	83.8	0	0.0	18	16.2

Metacarpal centers:

Table (7): Effect of maternal lamotrigine administration on metacarpal ossification centers of albino rat fetuses (Mc 1-3) .

Groups	No. of Fetuses	Total No of centers	Mean ± SD of complete centers	No of complete centers		No of incomplete centers		No of absent centers	
				No	%	No	%	No	%
GI(control)	68	204	3.00 ± 0.0	204	100.0	0	0.0	0	0.0
G IIa	47	141	3.00 ± 0.0	141	100.0	0	0.0	0	0.0
G IIb	37	111	2.50 ± 0.5***	93	83.8	0	0.0	18	16.2

Metatarsal centers:

Table (8): Effect of maternal lamotrigine administration of metatarsal ossification centers of albino rat fetuses (Mt 1-3) .

Groups	No. of Fetuses	Total No of centers	Mean± SD of complete centers	No of complete centers		No of incomplete centers		No of absent centers	
				No	%	No	%	No	%
GI (control)	68	204	3.00 ±0.0	204	100.0	0	0.0	0	0.0
G IIa	47	141	3.00 ±0.0	141	100.0	0	0.0	0	0.0
G IIb	37	111	2.50 ±0.5***	93	83.8	0	0.0	18	16.2

Skeletal anomalies:

Examination of skeleton of albino rat fetuses has been done in this study, using alizarin red stain, in which the ossification centers were taken as an indicator of fetal development. .

Bones of axial skeleton:

Table (1) showed that There is a very highly statistical significant reduction ($P<0.001$) in the mean of complete *craniofacial* ossification centers of treated groups. The incomplete centers were detected in treated groups (fig. 1, 2, 3, 4, 5, 6, 7, 8).

On *vertebral* ossification centers (25 bones were examined in each rat). There is a

very highly statistical significant ($P<0.001$) reduction in the mean of complete vertebral ossification centers of IIb group, while there is no statistically significant difference in those of IIa group when compared with control group. Absent centers were recorded only in group IIb (fig. 9 a, b)..

Table (3) showed that there is a very highly statistical significance reduction in the mean of complete *thoracic* ossification centers in IIb ($p<0.001$) in comparison with the control group. However, there is no statistically significant difference in mean of IIa group when compared with control group. Incomplete centers were not detected

in all groups, while absent centers were recorded only in group IIb (fig. 9 a, b).

Reduction in the mean of *lumber* ossification centers were observed only (6 bones were examined in each rat) in IIb group ($P<0.001$), while there is no statistically significant difference in mean of IIa group when compared with control group (table 4). Incomplete centers were not detected in all groups. While absent centers were recorded in IIb(fig. 9 a, b)..

Table (5) revealed that there is a very highly statistical significant ($P<0.001$) reduction in the mean of complete *sacral* ossification centers (4 bones were examined in each rat) of IIb group, while there is no statistically significant difference in mean of IIa when compared with control group. The incomplete centers were not detected in all groups, while absent centers were recorded only in group IIb (fig. 9 a, b).

Caudal ossification centers (table 6); showed a very highly statistical significant ($P<0.001$) reduction in the mean of complete ossification centers of IIb (3 bones were examined in each rat), while there is no statistically significant difference in mean of IIa group when compared with control group. Incomplete centers were not detected in all groups; while absent centers were recorded only in group IIb(fig. 9 a, b).

Examination of *metacarpal* ossification centers of albino rat fetuses (3 bones were examined in each rat) observed

a very high statistical significant ($P<0.001$) reduction in the mean of complete metacarpal ossification

Skeletal examination: Gross morphological examination of the fetuses in:

A- Therapeutic dose of lamotrigine treated group (IIa):

The skeletal examination by Alizarin red stain for fetuses in this group showed that the anomalies were found only in the skull, where *the parietal bones* showed *delayed ossification in the posterior part* (Fig. 4) and presence of *interparietal fissure* (fig. 5). *Exoccipital bone* showed severe *ossification delay* (fig. 5). About the *craniofacial bones* only the *maxilla* showed mild degree of delayed ossification (fig. 4). Other areas showed no anomalies.

B- 1/4 LD₅₀ of lamotrigine treated group (IIb):

Skeletal examination by Alizarin red stain in 1/4LD₅₀ treated lamotrigine group fetuses showed:

The parietal bone showed *delayed ossification in the lateral aspect* (Fig. 6) and in *the posterior aspect* (Fig. 7). *Interparietal fissure* showed in (fig. 8). *Delayed ossification* in both *Lacrimal* and *tympanic bones*, where *bulla* showed in (fig. 7). About the *craniofacial bones*, the *maxilla* showed variable degree of *ossification delay*: mild in (fig. 7) and moderate in (fig. 6). *The mandible* showed ossification delay as in its anterior aspect (body) (fig. 6).

Figure (1): Dorsal view of rat fetus from the control group showing the ossification centers:

- Supraoccipit (so).
- Exoccipit (eo).
- Scapula(s).
- Humerus (h).
- Ulna(u).
- Femur(f).
- Tibia (t).

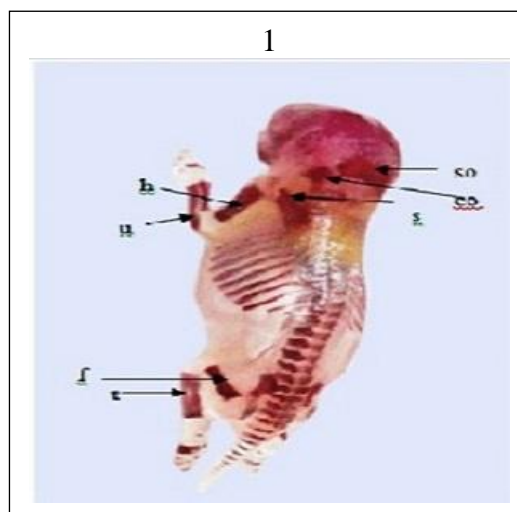


Figure (2): Lateral view of rat fetus from the control group showing the ossification centers:
 -Nasal bone(n).
 -Mandible (m).
 -Sternabrae(s).
 -Ribs(r).
 -Fibula (fi).
 -Metacarpal bones (mc).

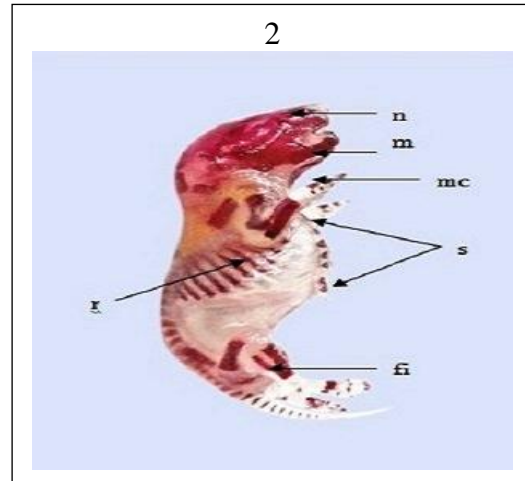


Figure (3): Dorsal view of rat fetus from the control group showing the ossification centers:
 -Vertebral column (vc).
 -Ilium (il).
 -Ischium (is).
 -Calcaneous(c).
 -Metatarsal bones (mt).

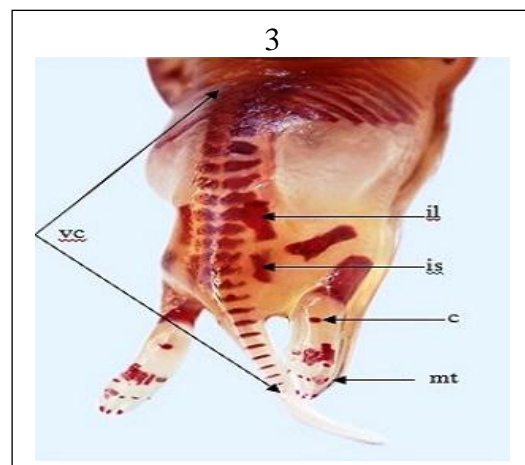


Figure (4): Lateral view of fetus from Lamotrigine treated group (GIIa) (Alizarin specimen), showing:
 1) Mild delayed ossification of maxilla.
 2) Delayed ossification of posterior part of parietal bones.

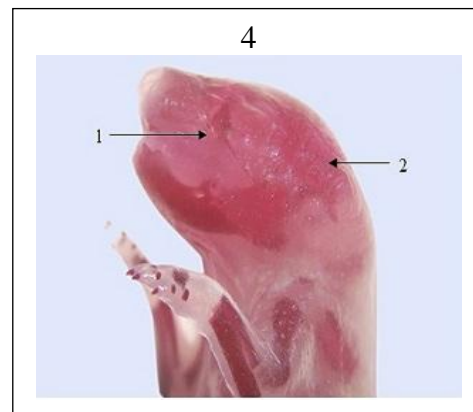


Figure (5): Dorsal view of fetus from Lamotrigine treated group (GIIa) (Alizarin specimen), showing:
 1) Present of interparietal fissure.
 2) Severe ossification delay of exoccipit bones.

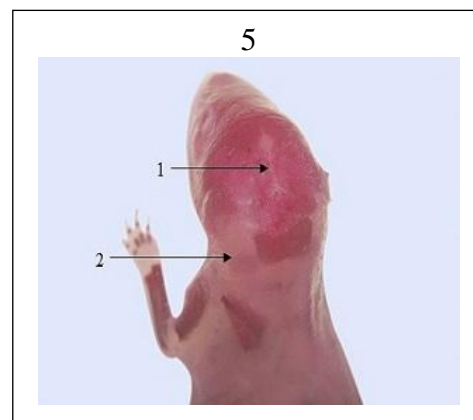


Figure (6): Lateral view of fetus from $\frac{1}{4}$ LD₅₀Lamotrigine treated group (GIb), (Alizarin specimen) showing:

- 1) Delayed ossification of lateral aspect of parietal bone.
- 2) Delayed ossification of maxilla.
- 3) Delayed ossification of the body of mandible.

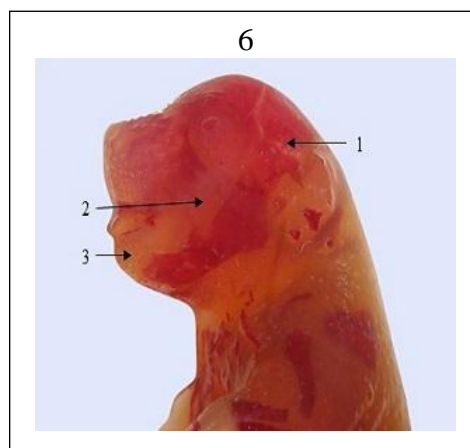


Figure (7): Lateral view of fetus from $\frac{1}{4}$ LD₅₀Lamotrigine treated group (GIb), (Alizarin specimen) showing:

- 1) Delayed ossification of posterior aspect of parietal bone.
- 2) Delayed ossification of maxilla.
- 3) Delayed ossification of lacrimal bone.
- 4) Delayed ossification of tympanic bulla.

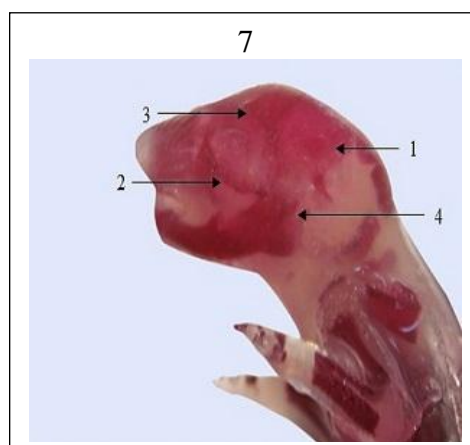


Figure (8): Dorsal view of fetus from $\frac{1}{4}$ LD₅₀Lamotrigine treated group (GIb), (Alizarin specimen) showing:

- 1) Widening of interparietal fissure.

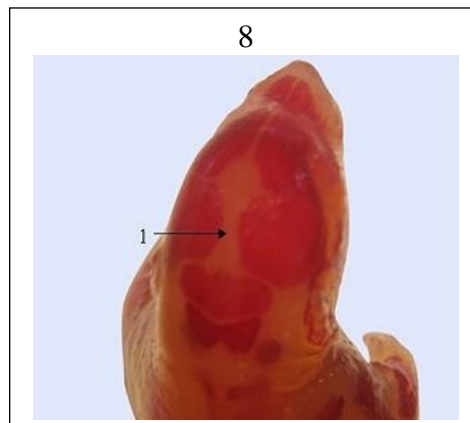


Figure (9a, b): Dorsal-oblique view of fetus from $\frac{1}{4}$ LD₅₀Lamotrigine treated group (GIb), (Alizarin specimens) showing complete absence of ossification centers.

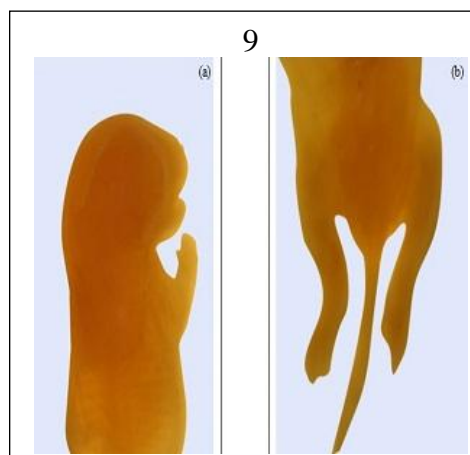


Figure (10): Ventral-Oblique view of fetus from $\frac{1}{4}$ LD₅₀ lamotrigine treated group (GIIb) (Alizarin specimen), showing:

- Delayed ossification in vertebral bodies and arches.

- Moderate ossification delayed in:

1) Humerus.

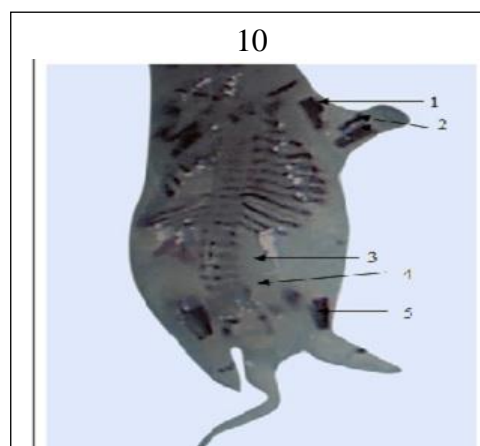
2) Radius and ulna.

- Severe ossification delayed in:

3) Ilium.

4) Ischium.

5) Femur.



DISCUSSION

The teratogenic effects of AEDs, were published 40 years ago. The use of antiepileptic drugs in pregnancy always presents challenges to doctors and their patients as they may have dangerous effects on the developing embryo. [16] The risks associated with in utero antiepileptic drug (AED) exposure are of considerable importance to the estimated children born to epileptic mothers. [7]

In current study we examine the ossification centers of:

The craniofacial centers:

The fetal ossification centers of different craniofacial regions showed decrease in the mean of ossification centers, in lamotrigine treated groups in comparison with the control group. In $\frac{1}{4}$ LD₅₀ of treated group, showed ossification delay in the craniofacial region. The most affected bones were the parietal with widening of interparietal fissure, lacrimal and tympanic bulla. The current findings are in line with Padmanabhan et al. (2003) and Elgndy et al (2016). [26]

-The vertebral ossification centers:

The fetal ossification centers of different regions of vertebral column showed non-significant change in the mean of complete ossification centers, in therapeutic treated group of lamotrigine. These results are in agreement with Gerenutti et al. (2008). [27] Kanda et al.(2017) reported that lamotrigine treatment did not affect bone strength or bone turnover. [28]

Decrease in the mean of complete ossification centers of $\frac{1}{4}$ LD₅₀ treated groups of the lamotrigine was recorded. This is consistent with Rahmani et al. (2006). [29] Moderate caudal dysgenesis (manifested by shortage in length of the components of the pelvic girdle with absence of caudal vertebrae) observed in fetal pelvic girdle obtained from lamotrigine-treated mothers. [30]

The fetal ossification centers of metacarpal bones showed very highly significant decrease in the mean of complete ossification centers in $\frac{1}{4}$ LD₅₀ lamotrigine in comparison with the control group. On contrary, Elgndy et al.(2016) showed absent ossification of metacarpal bones in therapeutic dose.

The fetal ossification centers of metatarsal bones showed no abnormalities in therapeutic doses, while decrease in the centers, in $\frac{1}{4}$ LD₅₀ treated group in comparison with the control group. Lamotrigine therapeutic dose appear to have low teratogenic risk. [31]

CONCLUSION

Therapeutic dose of lamotrigine is safe regarding skeletal ossification during pregnancy. Therefore; lamotrigine in therapeutic dose is the drug of choice to be used by epileptic pregnant women.

REFERENCES

1. Goldenberg MM. Overview of Drugs Used For Epilepsy and Seizures. P T. 2010; 35(7): 392–415.

2. Morrow J, Russell A, Guthrie E, et al. Malformation risks of antiepileptic drugs in pregnancy: a prospective study from the UK Epilepsy and Pregnancy Register. *J. Neurol. Neurosurg. Psychiatry*, 2006; 77(2):193-8.
3. Borgelt LM, Hart FM, and Bainbridge JL: Epilepsy during pregnancy: focus on management strategies. *Int J Womens Health*. 2016; 8: 505–517.
4. Beghi E, and Hesdorffer D. Prevalence of epilepsy - an unknown quantity. *Epilepsia* 2014; 55: 963-967.
5. Maehara T: Neuroimaging of epilepsy. *Neuropathology*, 2007; 27(6):585-93.
6. Eroglu E., Gokcil Z., Bek S. et al. Pregnancy and teratogenicity of antiepileptic drugs. *Acta Neurol. Belg.* 2008; 108(2):53-7.
7. Meador K. J. Effects of In Utero Antiepileptic Drug Exposure. *Epilepsy Curr.* 2008; 8(6): 143– 7.
8. Tatum W. O. Balancing the risks to the fetus from epileptic seizures and antiepileptic drug exposure in pregnancy. *Expert. Rev. Neurother.* 2009; 9(12):1707-8.
9. Palac S, Meador KJ. Antiepileptic drugs and neurodevelopment: an update. *Curr Neurol Neurosci Rep.* 2011; 11(4):423-7.
10. Prakash, Prabhu L. V. , Rai R., et al. A: Teratogenic effects of the anticonvulsant gabapentin in mice. *Singapore Med. J.* 2008; 49(1):47-53.
11. Gedzelman E and Meador KJ. Antiepileptic drugs in women with epilepsy during pregnancy. *Ther Adv Drug Saf.* 2012; 3(2): 71–87.
12. Ban L, Fleming KM, Doyle P, et al. Congenital Anomalies in Children of Mothers Taking Antiepileptic Drugs with and without preconceptional High Dose Folic Acid Use: A Population-Based Cohort Study. *PLoS One.* 2015; 10(7): e0131130.
13. Tomson T. and Battino D. Teratogenic effects of antiepileptic drugs. *Seizure.* 2008; 17(2) : 166- 71.
14. La Roche, S.M. and Helmers S.L. The new antiepileptic drugs: clinical applications. *J.A.M.A.* 2004; 291(5): 615-20.
15. Bootsma H.P., Vos A.M., Hulsman J., et al. Lamotrigine in clinical practice: Long-term experience in patients with refractory epilepsy referred to a tertiary epilepsy center. *Epilepsy Behav.* 2008; 12(2):262–8.
16. Prakash, Prabhu L.V., Nasar M. A., et al. Lamotrigine in pregnancy: safety profile and the risk of malformations. *Singapore Med. J.* 2007; 48 (10) : 880- 3.
17. Abdelsayed M and Sokolov S. Voltage-gated sodium channels. *Channels (Austin)*. 2013; 7(3): 146–152.
18. Vajda F.J., Hitchcock A., Graham J., Solinas C., O'Brien T.J., Lander C. M. and Eadie M.J: Foetal malformations and seizure control: 52 months data of the Australian Pregnancy Registry. *Eur. J. Neurol.* 2006; 13:645–54.
19. Czapinski P., Blaszczyk B. and Czuczwar S.J. Mechanism of action of antiepileptic drugs. *Curr. Top. Med Chem.* 2005; 5(1): 3– 14. .
20. Padmanabhan R., Abdulrazzaq Y.M., Bastaki S.M., et al. Experimental studies on reproductive toxicologic effects of lamotrigine in mice. *Birth Defects Res. B. Dev. Reprod. Toxicol.* 2003; 68(5):428-38.
21. Shedrack I, Nwocha UC and Ikechukwu IJ. A new and simple method of confirmatory detection of mating in albino rats (*Rattus norvegicus*). *Animal Research International.* 2006; 3(3): 527 – 530.
22. Paget G.E. and Barnes J. M. Toxicological tests in evaluation of drug activities. Edited by: Laurence D.R. *Pharmacometrics*. New York: Acad. Press. 1964; 13:134-5.
23. Active ingredient. Lamotrigine - brands, medical use, clinical data, available in: <http://www.caymanchem.com/msdss/15428.pdf>. (Accessed at January 2008)
24. Richmond G. and Bennett L. Clearing and staining of embryos for demonstrating ossification. *Stain technology.* 1938; 13:77-9.
25. Khera K.S. Maternal toxicity of drugs and metabolic disorders- a possible etiologic factor in the intrauterine death and congenital malformation: a critique on human data. *Crit. Rev. Toxicol.* 1987; 17: 345–75.
26. Elgindy I.S, Hagag O.G, EL Kholy S.M, et al. A Comparative study of the teratogenic effects of antiepileptic drugs: Lamotrigine and levetiracetam on adult albino rats. *Egypt J. Forensic Sci. Appl. Toxicol.* 2016; 16 (2).
27. Gerenutti M., De Oliveira C.C., De Miranda A.C.R., et al. Reproductive performance and embryotoxicity of rats exposed to carbamazepine. (*revista Brasileira de Ciencias Farmaceuticas (R.B.C.F.)*. 2008; 44(3):509- 14.

28. Kanda J, Izumo N, Kobayashi Y, et al. Effects of the antiepileptic drugs topiramate and lamotrigine on bone metabolism in rats. *Biomed Res.* 2017; 38(5):297-305.
29. Rahmani, F., Delaram, M., and Forouzandeh, N. The teratogenic effects of Lamotrigine on mouse fetus. *J Reprod Infertil.* 2006;7:45-52.
30. Martinez Ferri M, Peña Mayor P, PerezLópez-Fraile I, et al. Comparative study of antiepileptic drug use during pregnancy over a period of 12 years in Spain. Efficacy of the newer antiepileptic drugs lamotrigine, levetiracetam, and oxcarbazepine. *Neurologia.* 2018;33(2):78-84.
31. Gedzelman E and Meador KJ. Antiepileptic drugs in women with epilepsy during pregnancy. *TherAdv Drug Saf.* 2012; 3(2): 71–87.

How to cite this article: Kutb MAM, Omer HAM. Skeletal effect of lamotrigine Administration in pregnant albino rats. *International Journal of Science & Healthcare Research.* 2019; 4(2): 1-10.
